Odontogenic Cysts and Tumors
What is New in the 5th Edition of the W.H.O. Classification and New Information on Some (Newer/Well-Established) Entities

IOANNIS G. KOUTLAS, DDS, MS

ASSOCIATE PROFESSOR

SCHOOL OF DENTISTRY, UNIVERSITY OF MINNESOTA

DIRECTOR

UNIVERSITY OF MINNESOTA ORAL PATHOLOGY LABORATORY

A long list of cysts

7.1: Cysts of the jaws

- 7.1.0.1: Radicular cyst
- 7.1.0.2: Inflammatory collateral cysts
- 7.1.0.11: Surgical ciliated cyst
- 7.1.0.10: Nasopalatine duct cyst
- 7.1.0.6: Gingival cysts
- 7.1.0.3: Dentigerous cyst
- 7.1.0.9: Orthokeratinized odontogenic cyst
- 7.1.0.5: Lateral periodontal cyst and botryoid odontogenic cyst
- 7.1.0.8: Calcifying odontogenic cyst
- 7.1.0.7: Glandular odontogenic cyst
- 7.1.0.4: Odontogenic keratocyst

Giant cell lesions and bone cysts

- 7.7.0.1: Central giant cell granuloma
- 7.7.0.2: Peripheral giant cell granuloma
- 7.7.0.3: Cherubism
- 7.7.0.4: Aneurysmal bone cyst
- 7.7.0.5: Simple bone cyst

A long list of cysts

Table 1 WHO Classification of Odontogenic and maxillofacial bone tumours, 2022 versus 2017. Main headings are arranged in the order of the 2022 classification; within sub-headings, lesions are presented in the original order of each classification

2022 Classification	2017 Classification*	
Cysts of the jaws	Odontogenic cysts of inflammatory origin	Odontogenic & non-odontogenic developmental cysts
Radicular cyst	Radicular cyst	Dentigerous cyst
Inflammatory collateral cysts	Inflammatory collateral cysts	Odontogenic keratocyst
Post-surgical ciliated cyst		Lat. periodontal cyst and botryoid cyst
Nasopalatine duct cyst		Gingival cyst
Gingival cyst		Glandular odontogenic cyst
Dentigerous cyst		Calcifying odontogenic cyst
Orthokeratinized odontogenic cyst		Orthokeratinized odontogenic cyst
Lat. periodontal cyst and botryoid cyst		Nasopalatine duct cyst
Calcifying odontogenic cyst		
Glandular odontogenic cyst		
Odontogenic keratocyst		

Vered and Wright Head and Neck Pathol 2022;16:63

Postsurgical ciliated cyst

- Maxilla and rare cases in the mandible after reconstructive or orthognathic surgeries.
- Mandible can look like sinus even with presence of eosinophils !

  Koutlas et al. J Oral Maxillofac Surg 2002;60:324

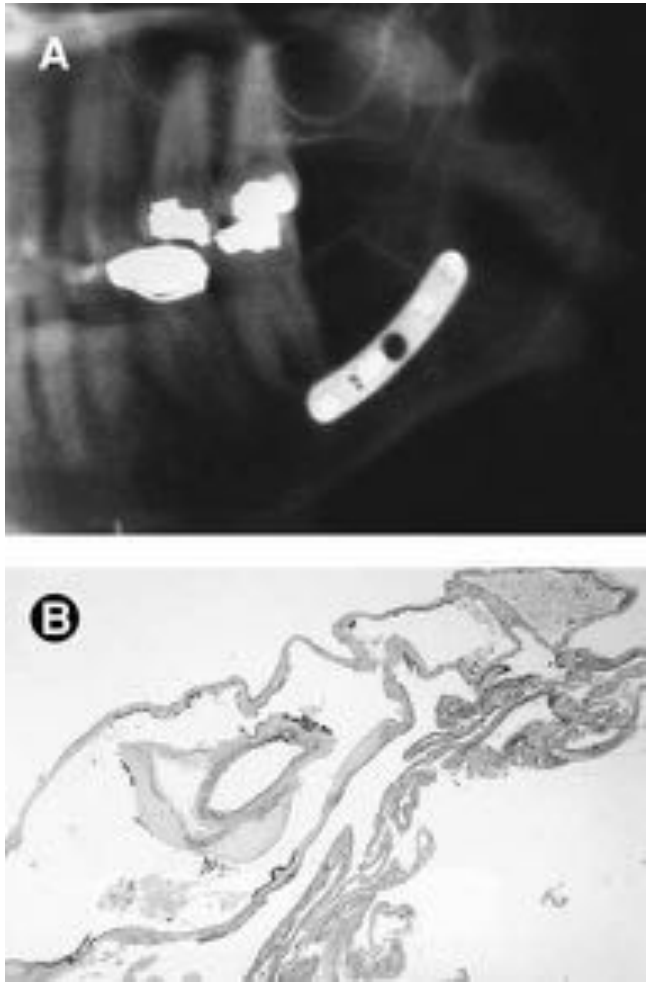

Aneurysmal bone cyst

- Aneurysmal bone cyst (ABC) is a cystic or multicystic, expansile, osteolytic neoplasm composed of blood-filled sinusoidal spaces lined by fibrous septa that contain osteoclast-type giant cells.
- The terms primary and secondary not used anymore
- *USP6::CDH11* fusion in 70% of cases
  - Other partners for *USP6* exist
- 1.5% of cases arise in the jaws
- Painful enlargement
- Tooth mobility and displacement, root resorption, maxillary tumors may lead to exophthalmos
- Unilocular or multilocular radiolucency


Courtesy Dr. Stich


5 moths after
Courtesy Dr. Stich

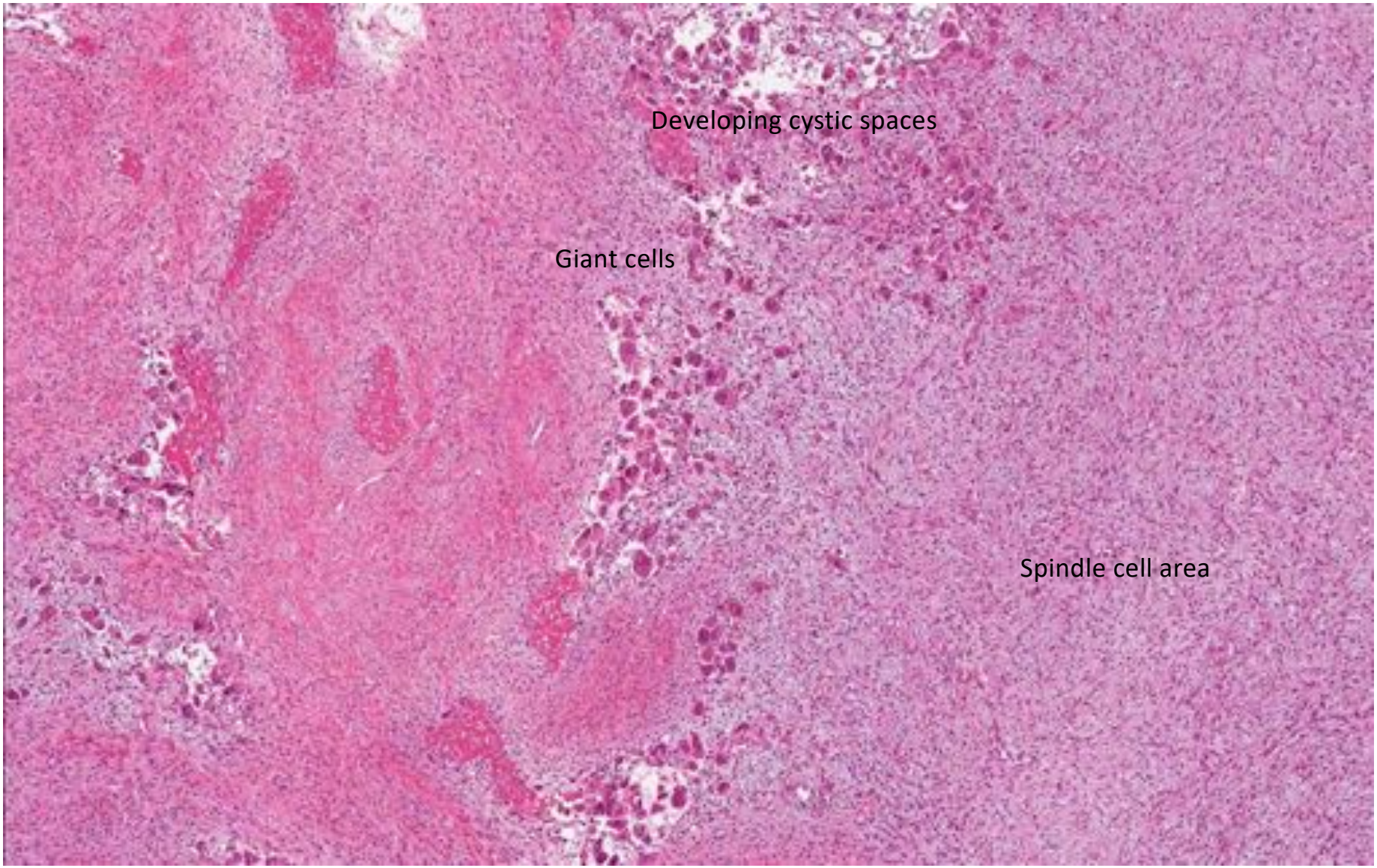
Developing cystic spaces
Giant cells
Spindle cell area

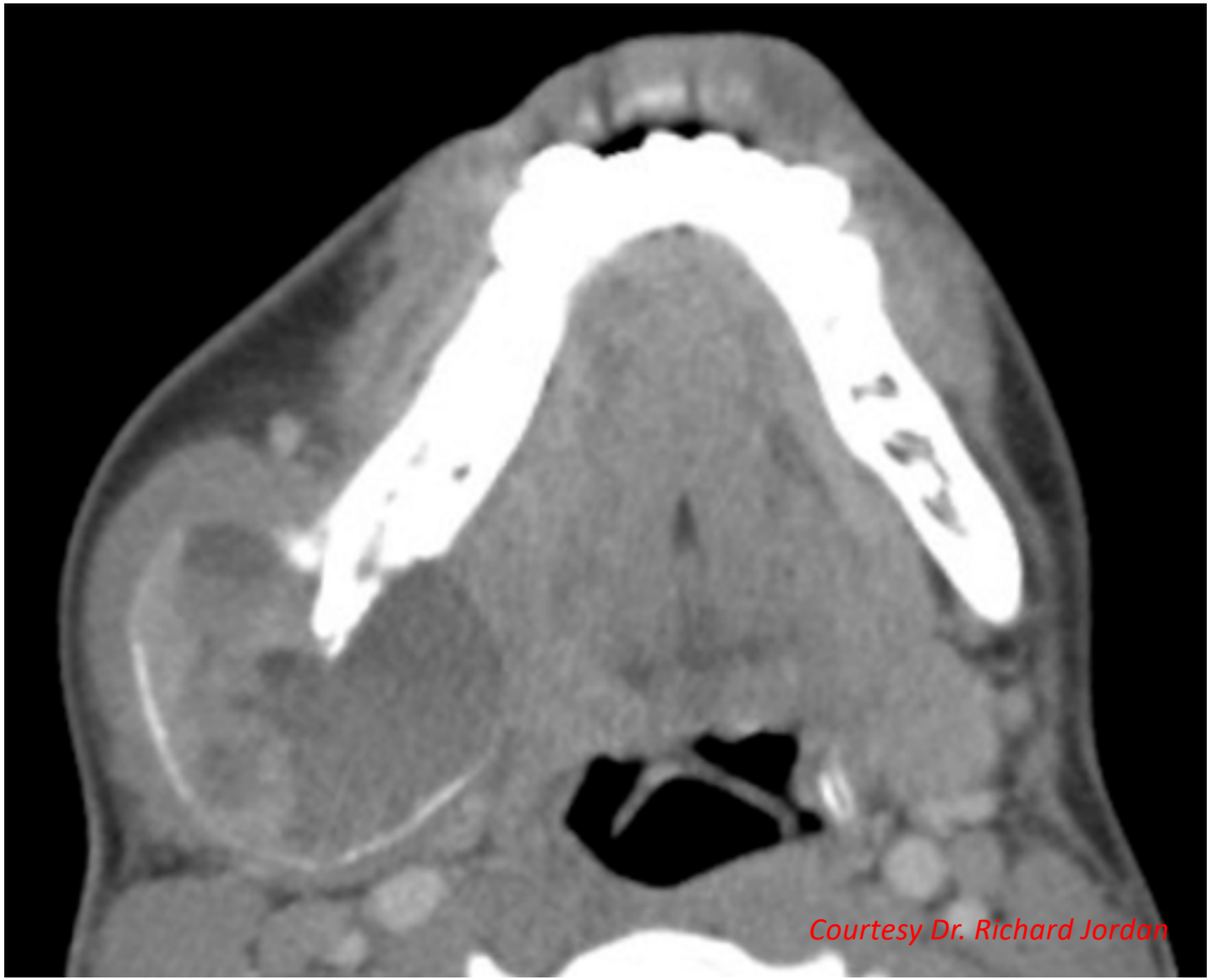
Courtesy Dr. Richard Jordan

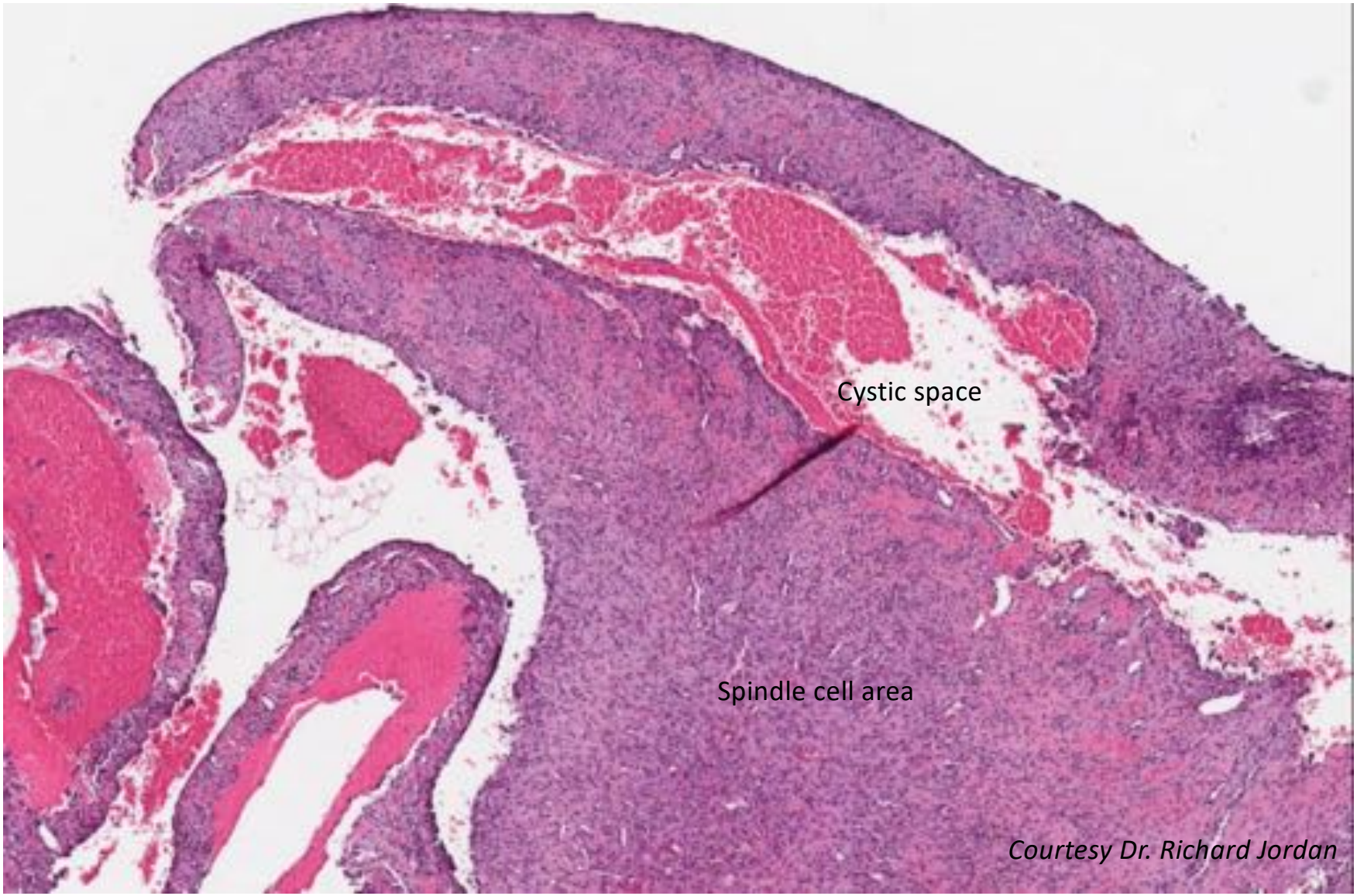
Cystic space
Spindle cell area
Courtesy Dr. Richard Jordan

Benign epithelial odontogenic tumors (2022)	Benign epithelial odontogenic tumors (2017)
Adenomatoid odontogenic tumor (I have doubts)	Ameloblastoma
Squamous odontogenic tumour	-Ameloblastoma, unicystic type
Calcifying epithelial odontogenic tumour	-Ameloblastoma, extraosseous/peripheral type
Ameloblastoma, extraosseous/peripheral	-Metastasizing ameloblastoma
Ameloblastoma, unicystic	Squamous odontogenic tumour
Ameloblastoma, conventional	Calcifying epithelial odontogenic tumour
Adenoid ameloblastoma (new)	Adenomatoid odontogenic tumour
Metastasizing ameloblastoma !	

Molecular advancements and Newer Treatments

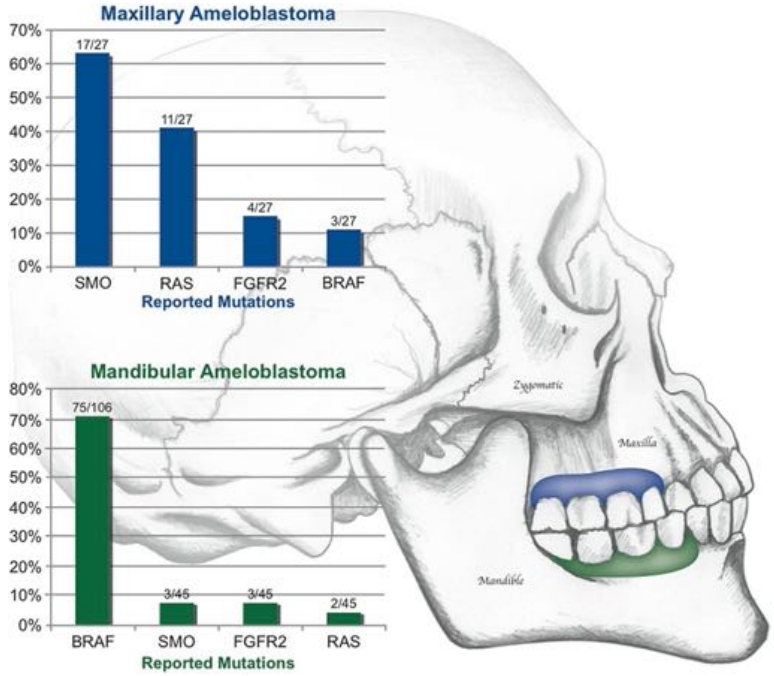

- *BRAF*^{V600E} mutations in >70% of mandibular ameloblastomas (*RAS, FGFR2, SMO*)
- *SMO* mutations in > 50% of maxillary ameloblastomas (*RAS, FGFR2, BRAF*)
- Inhibitors of BRAF are being used to treat solid ameloblastomas
- Stops proliferation of cells and may shrink the tumors
- Use of BRAF VE1 antibody in some cases.

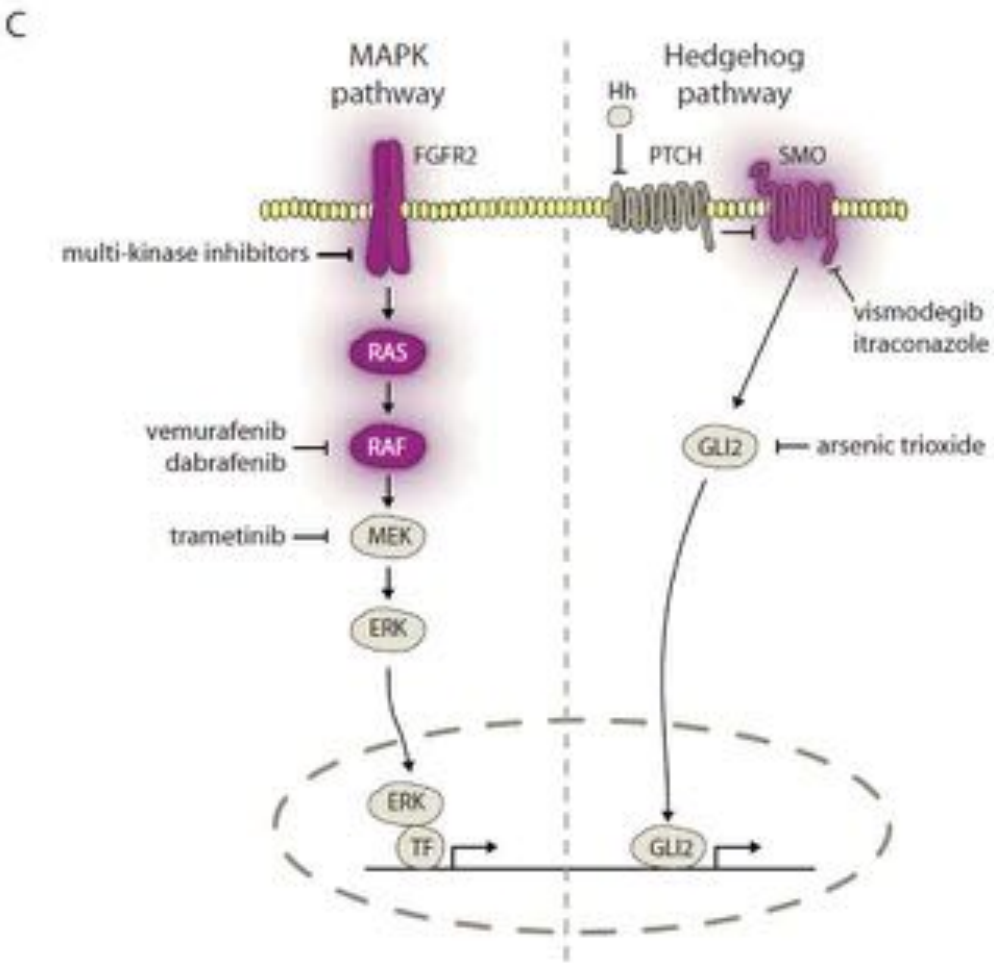

OXFORD

JNCI J Natl Cancer Inst (2015) 107(1): dju378

doi:10.1093/jnci/dju378
First published online December 3, 2014
Correspondence

CORRESPONDENCE

Clinical and Radiographic Response With Combined BRAF-Targeted Therapy in Stage 4 Ameloblastoma

Frederic J. Kaye, Alison M. Ivey, Walter E. Drane, William M. Mendenhall, Robert W. Allan

Dabrafenib (Tafinlar) 150mg bid & Trametinib (Mekinist) 2mg/d

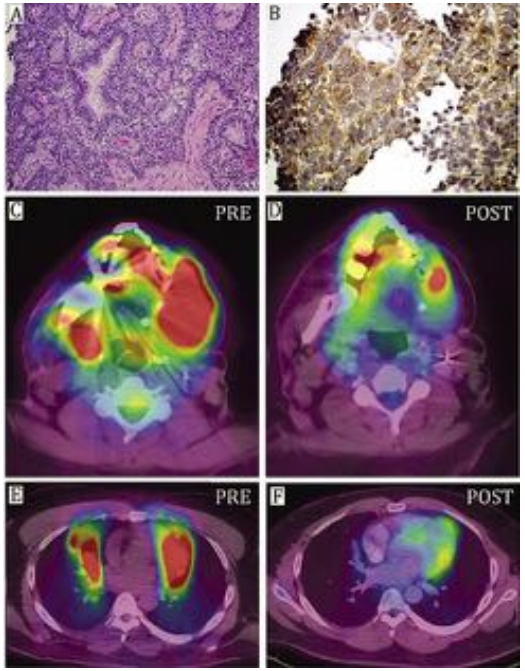

Auxiliary immunohistochemistry

Calretinin

- 29-kDa calcium binding protein
- Suprabasal staining (stellate reticulum-like) and superficial layer
- Same for unicystic with the V-G criteria
- Some say that calretinin immunohistochemistry is of no use.

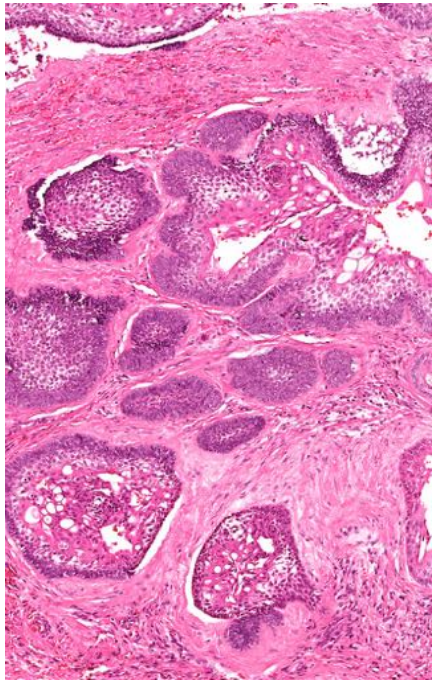

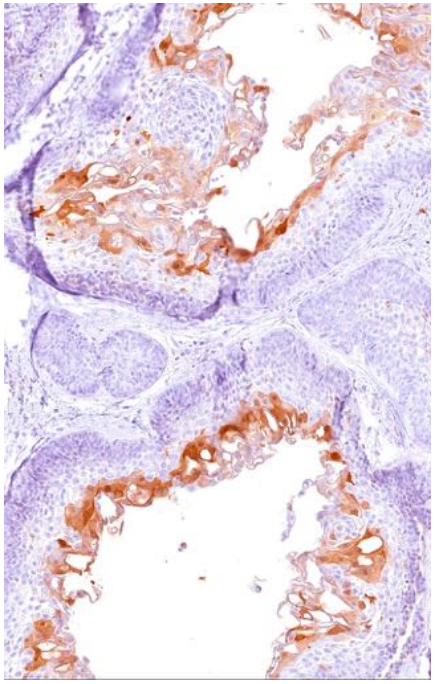

Auxiliary immunohistochemistry

CD56

- NCAM
  - Neural cell adhesion molecule
- Expression in odontogenesis
- Cairns et al. Histopathol 2010;57:544

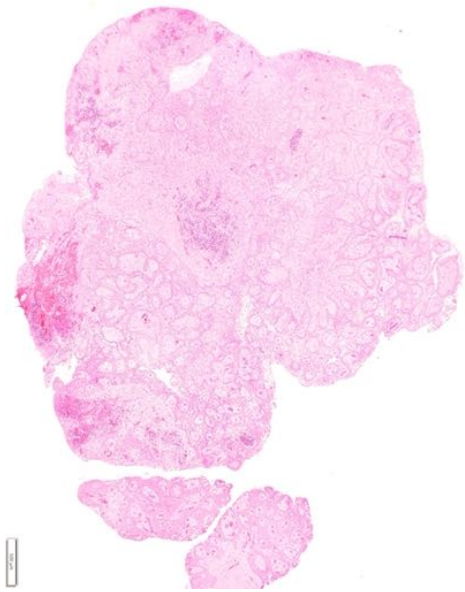

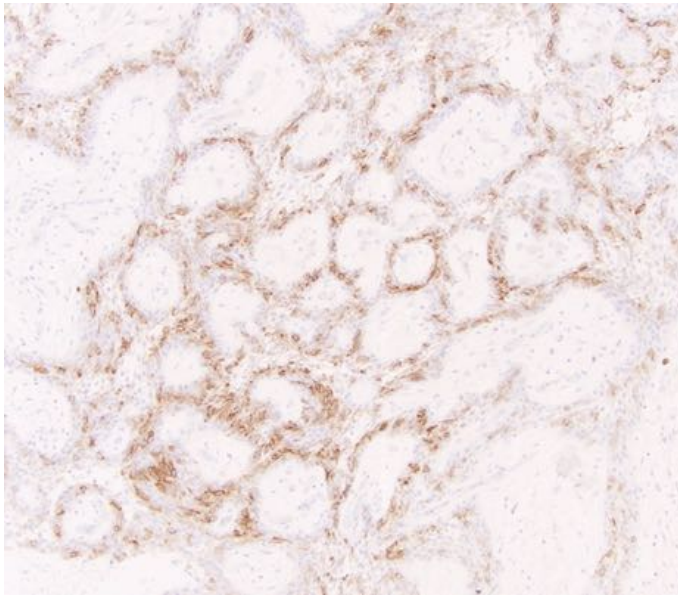

Auxiliary immunohistochemistry

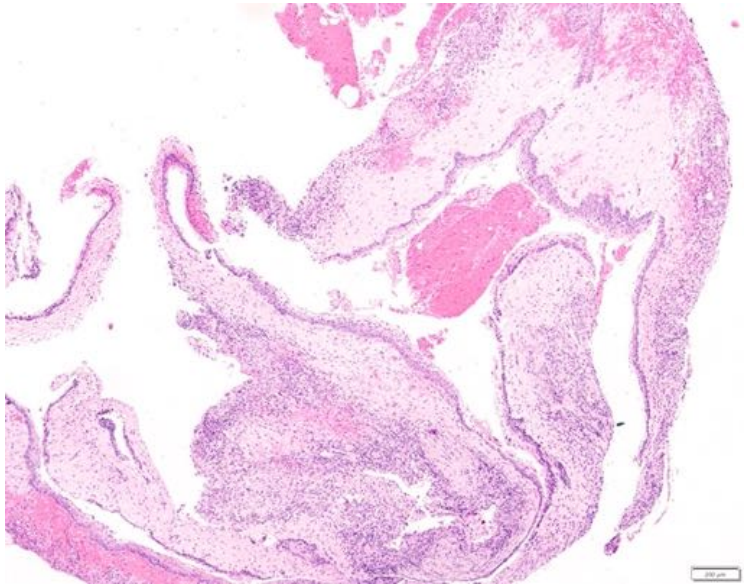

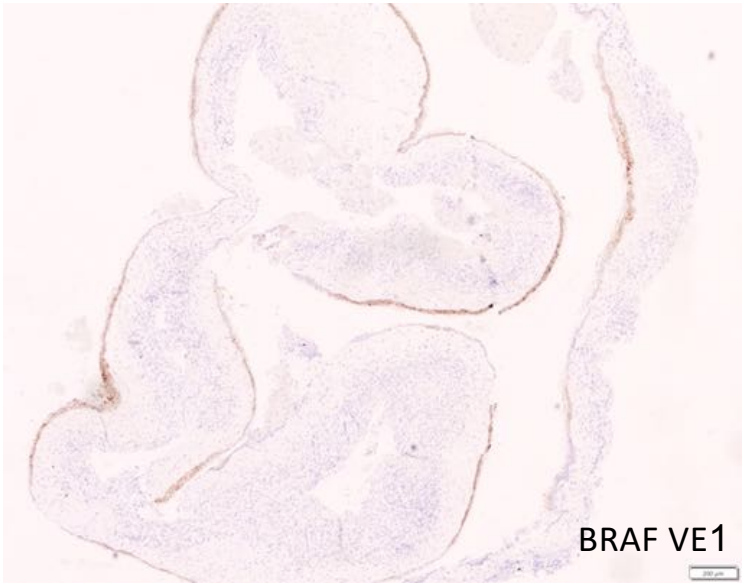

23-year-old male with marginally expansile radiolucency

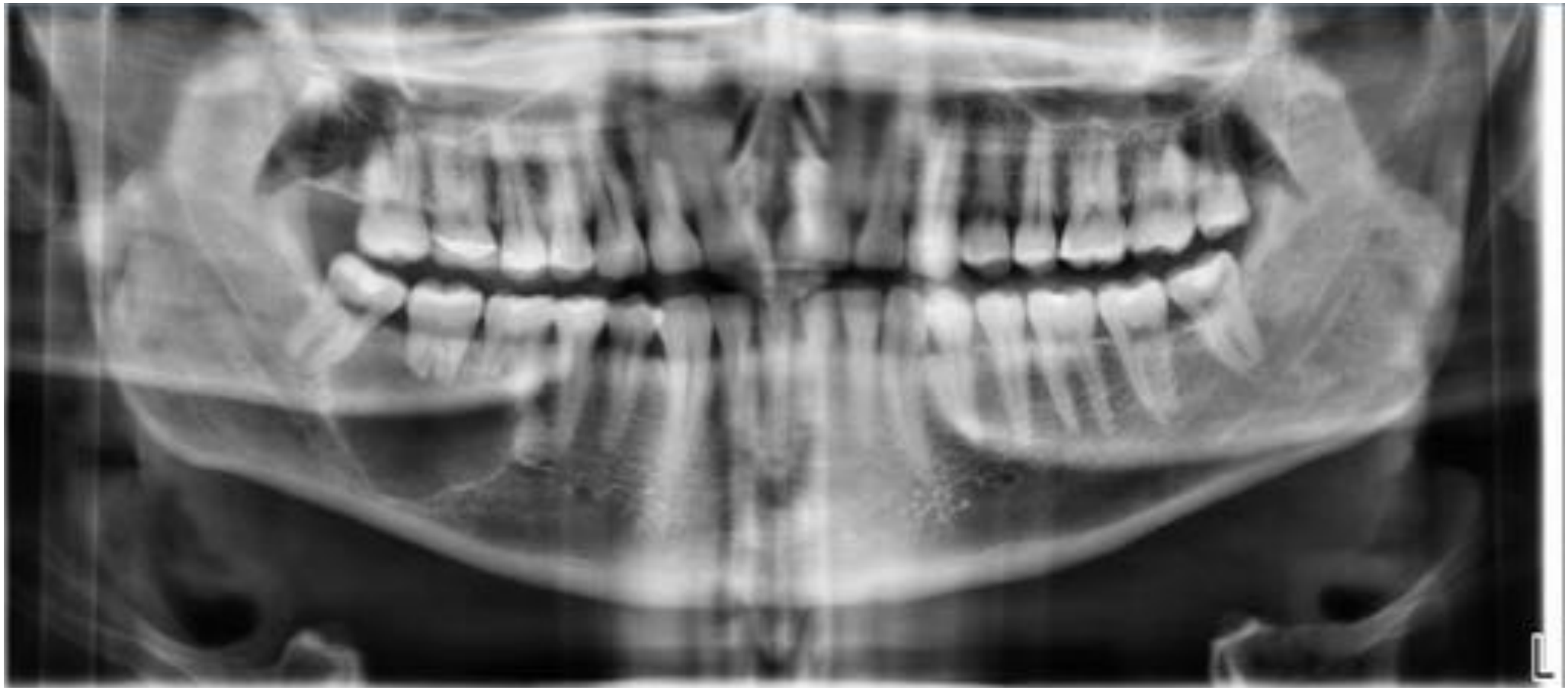
L

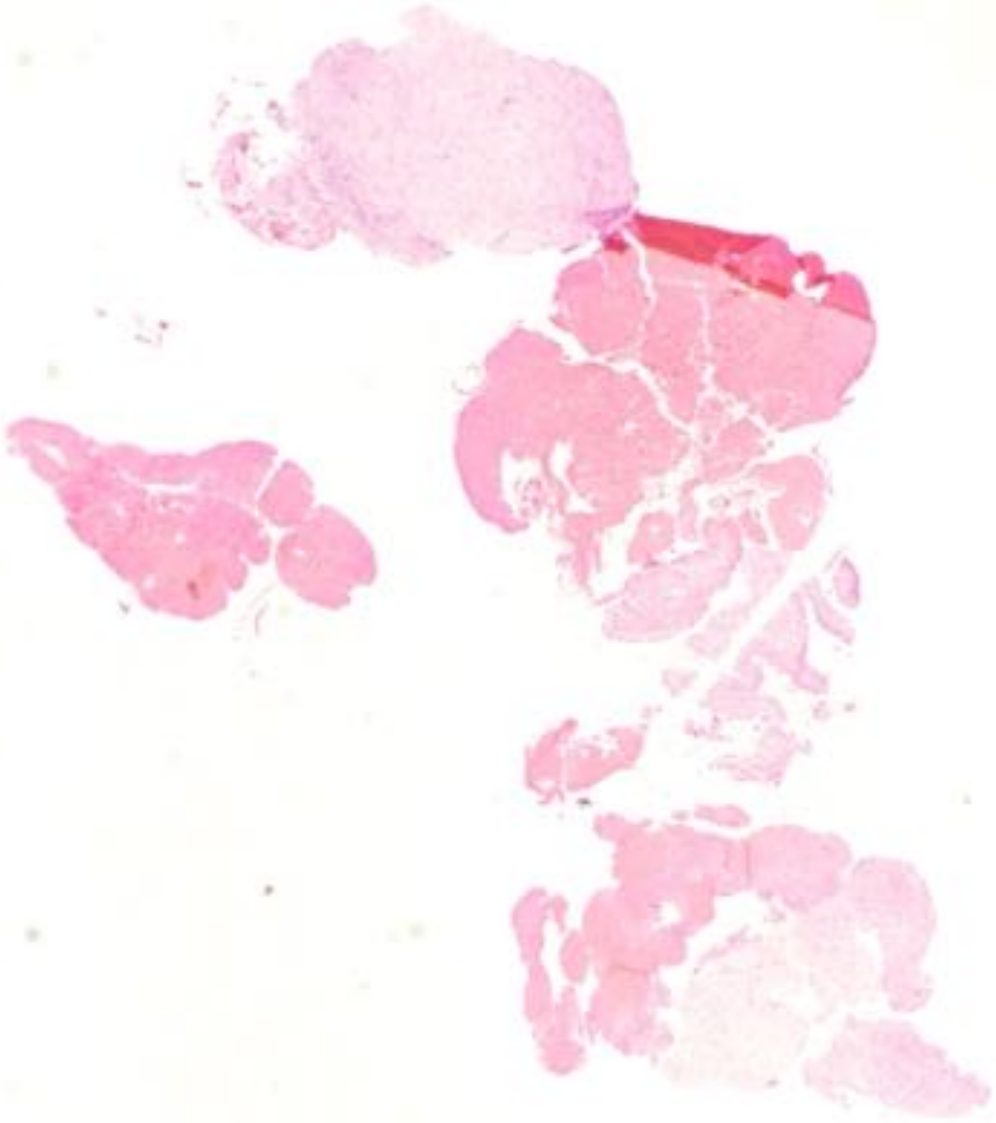

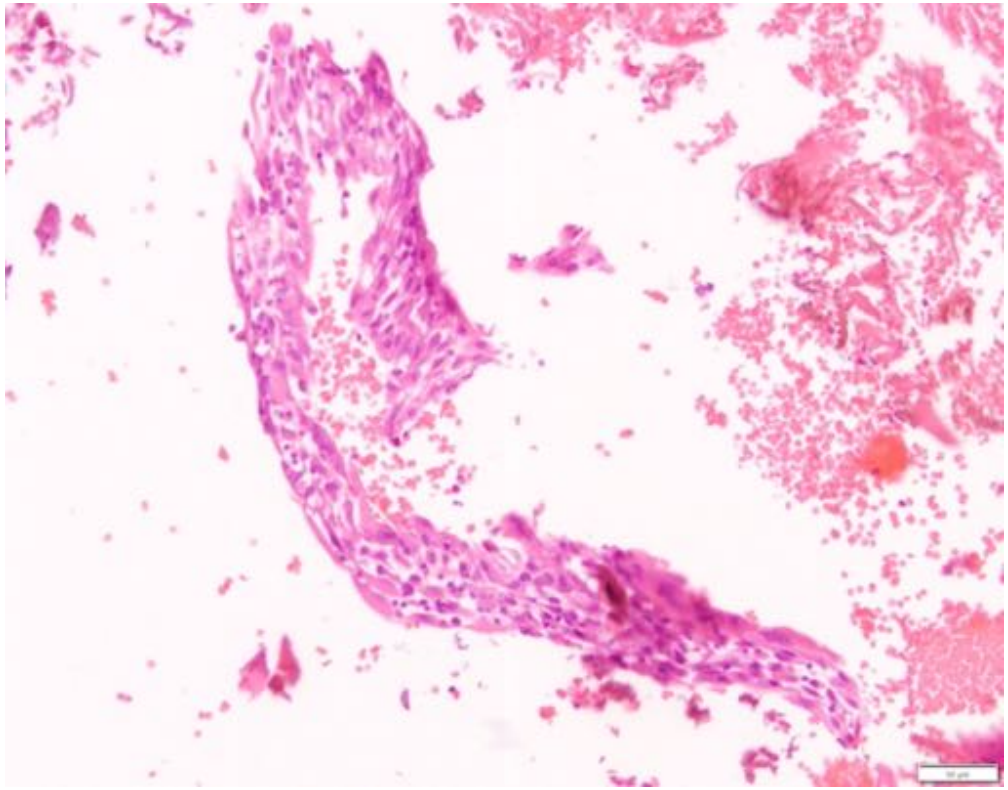

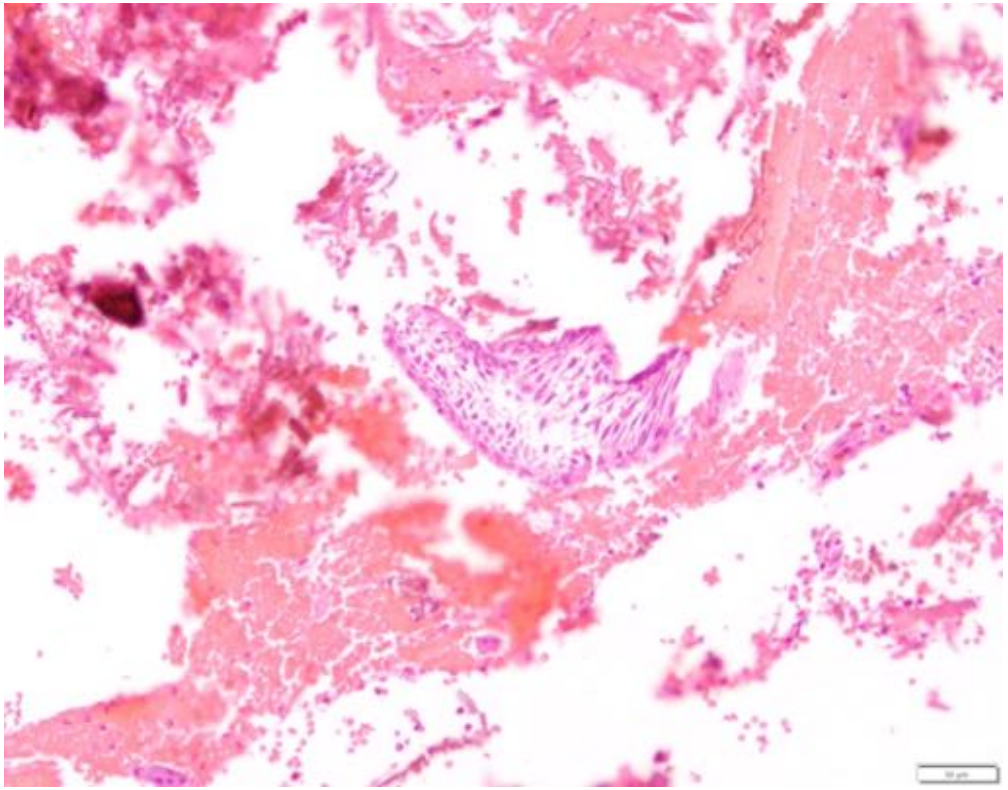

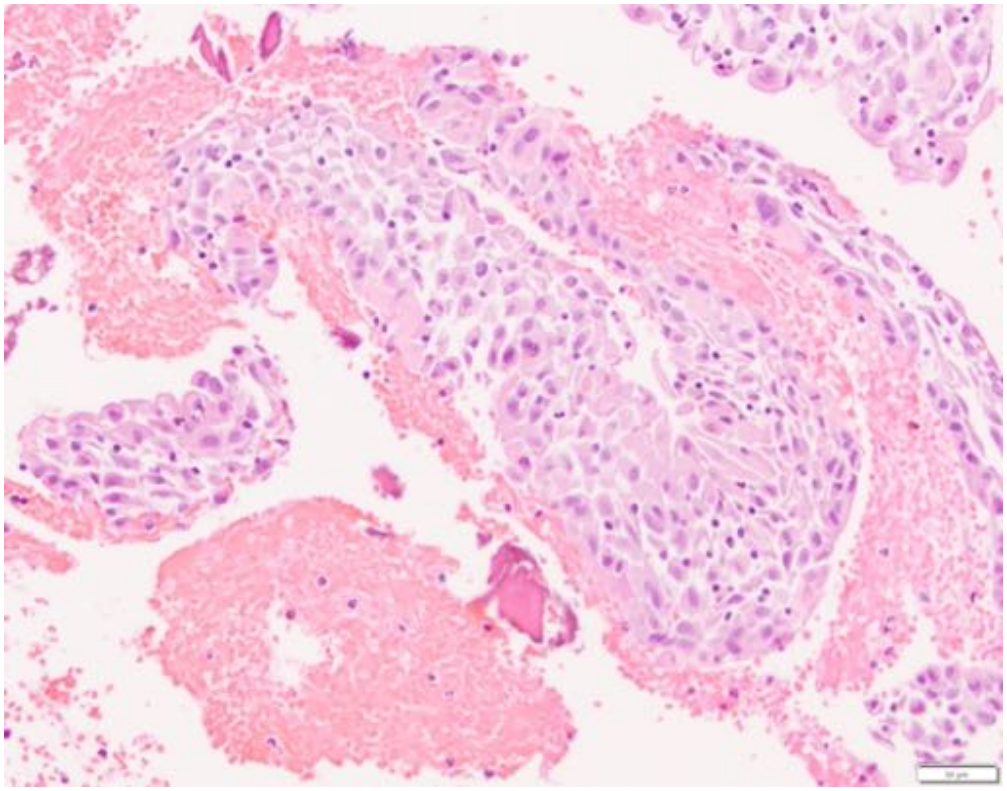

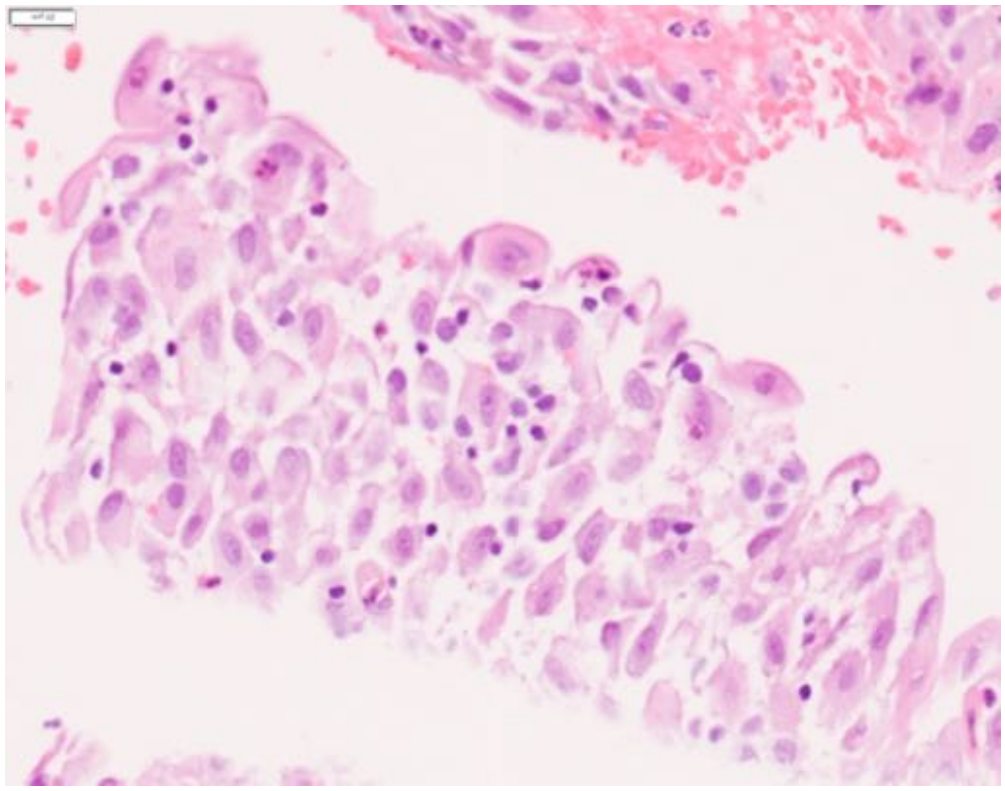

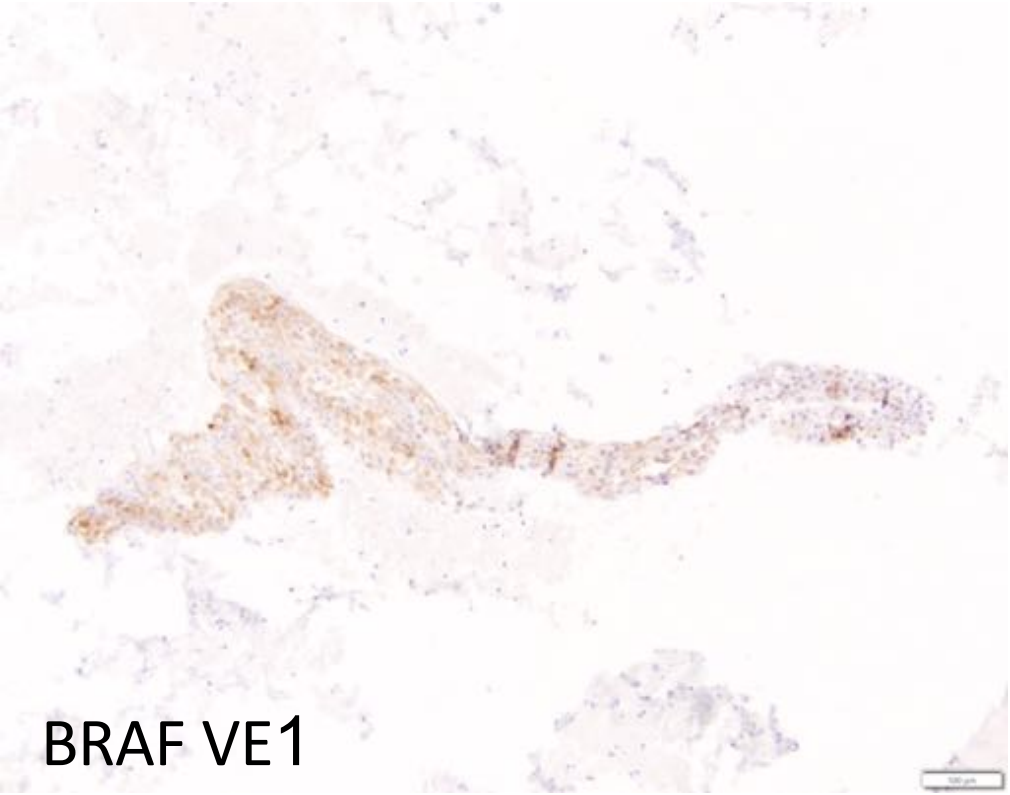
BRAF VE1

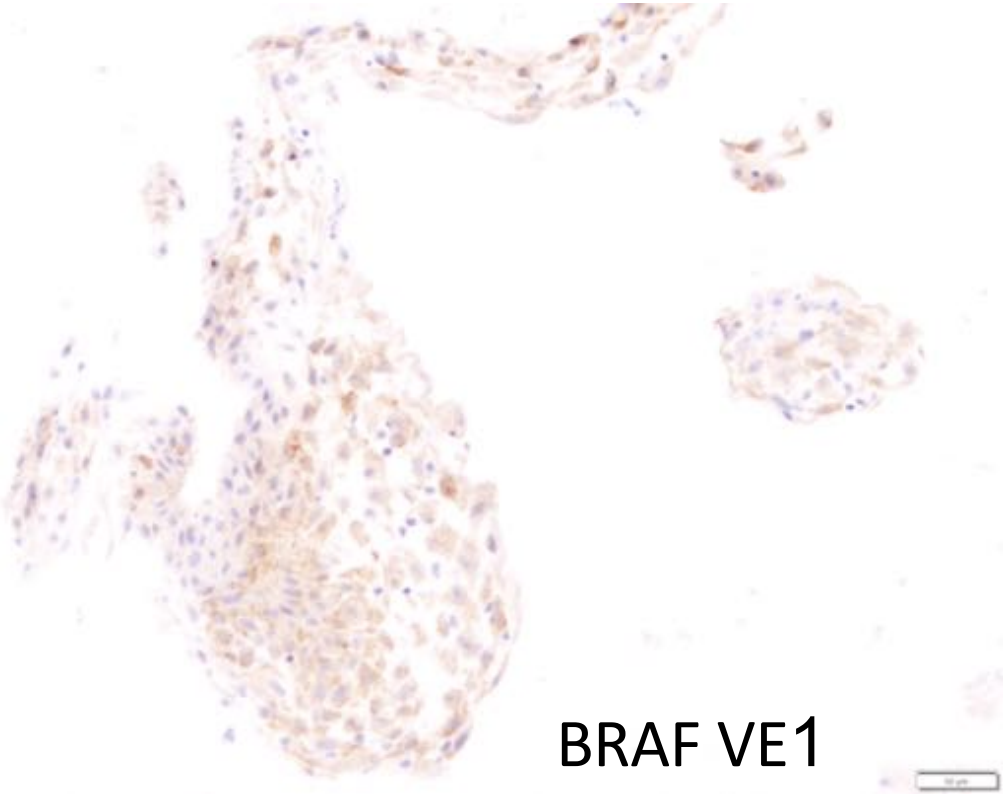
BRAF VE1

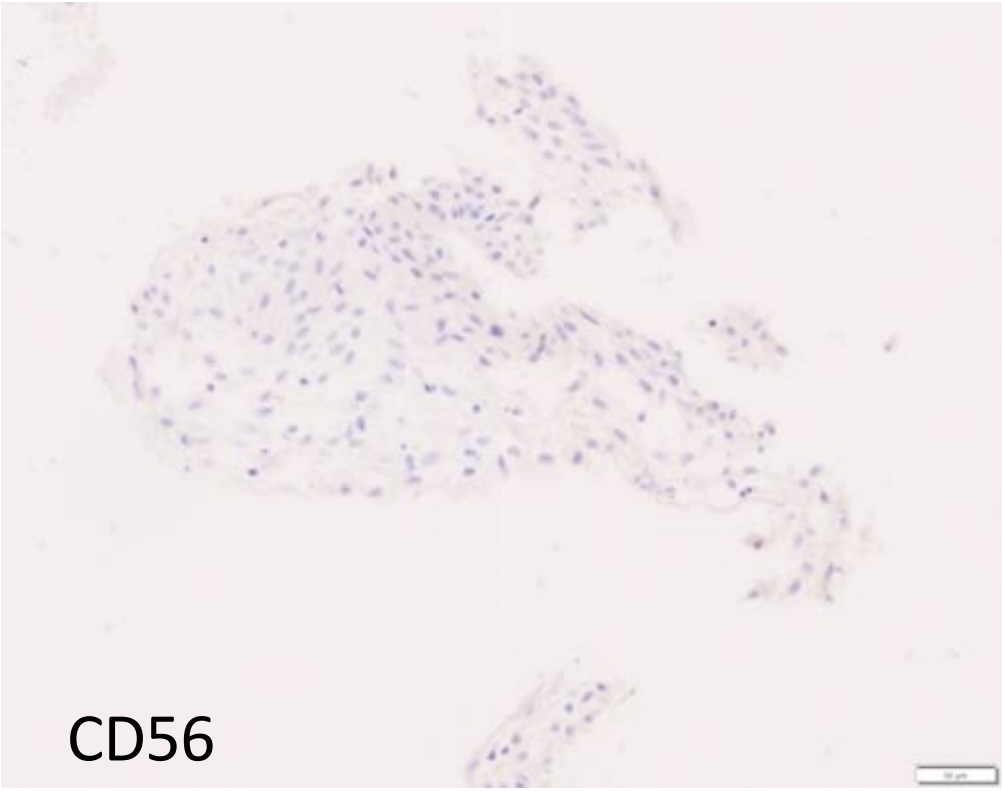
CD56

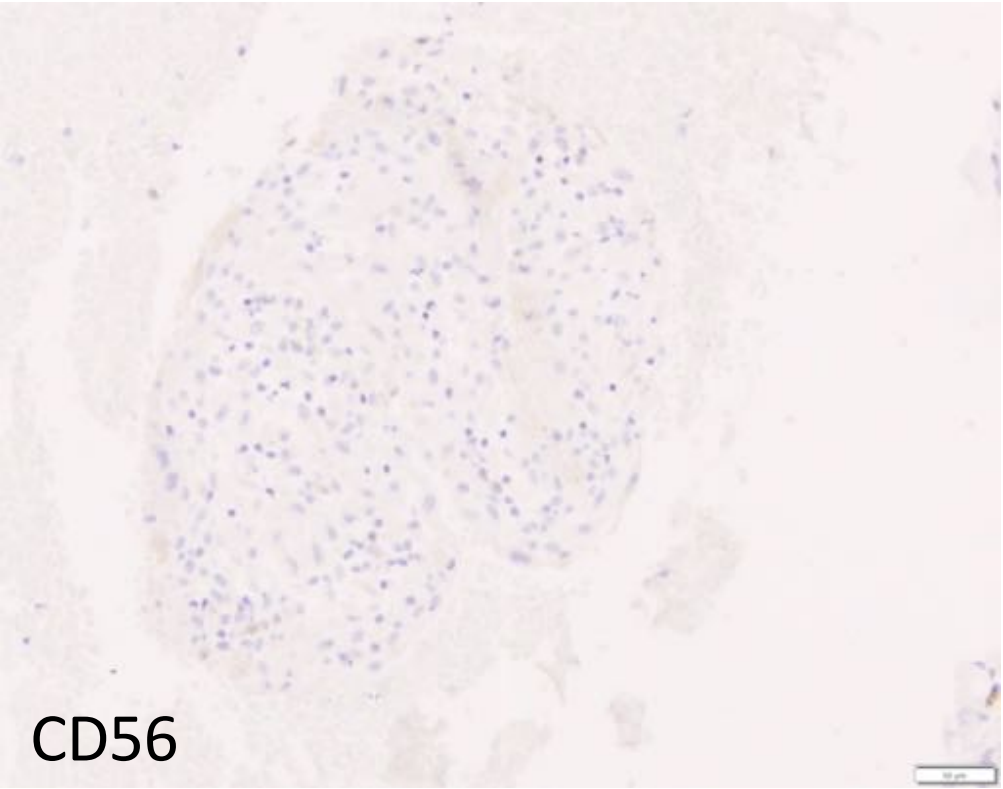
CD56

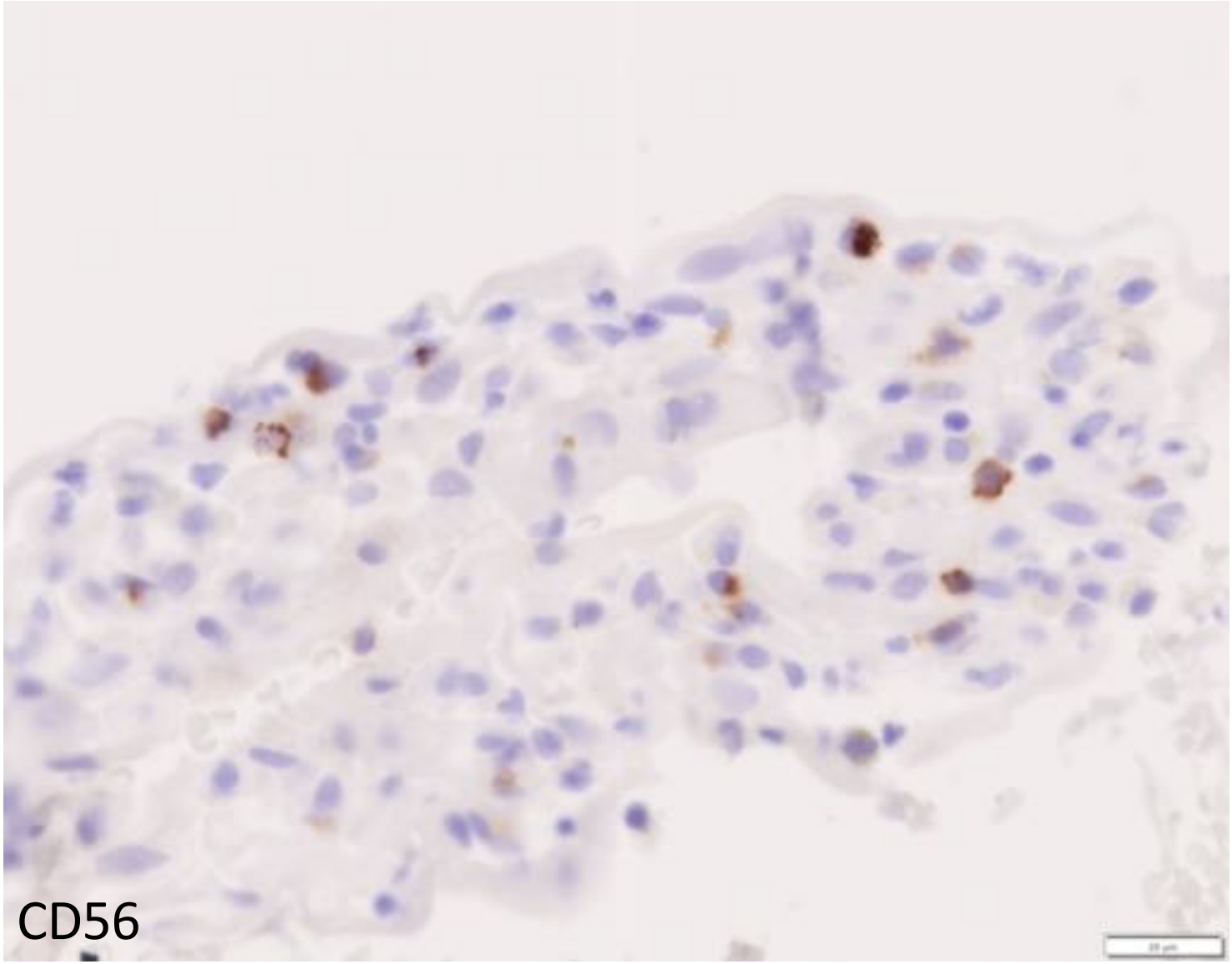
CD56

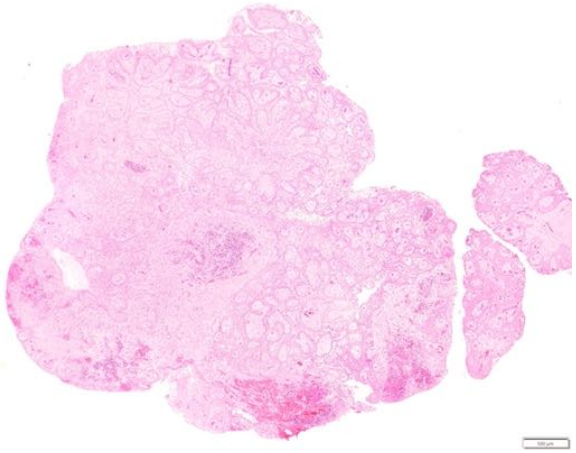

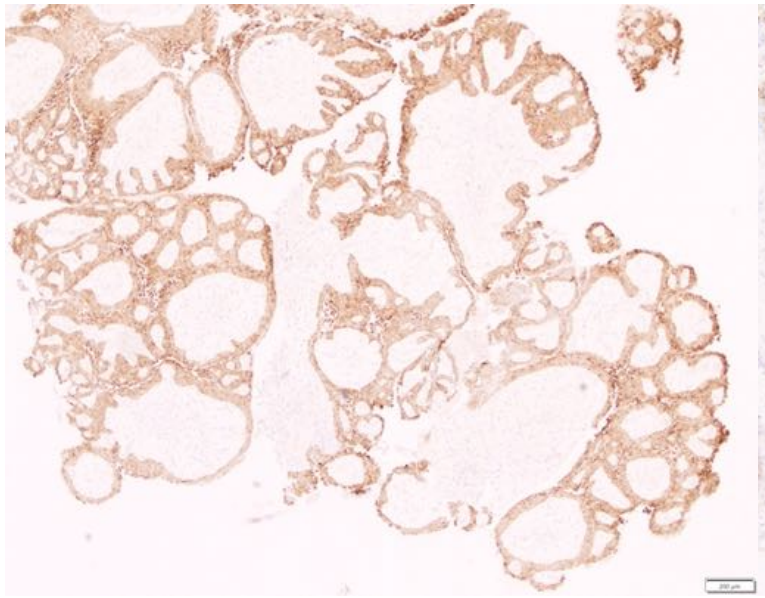

BRAF VE1

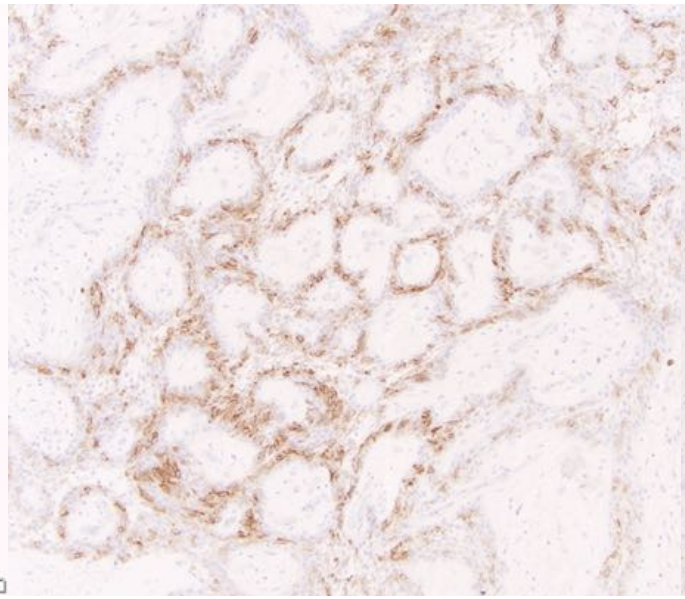

CD56

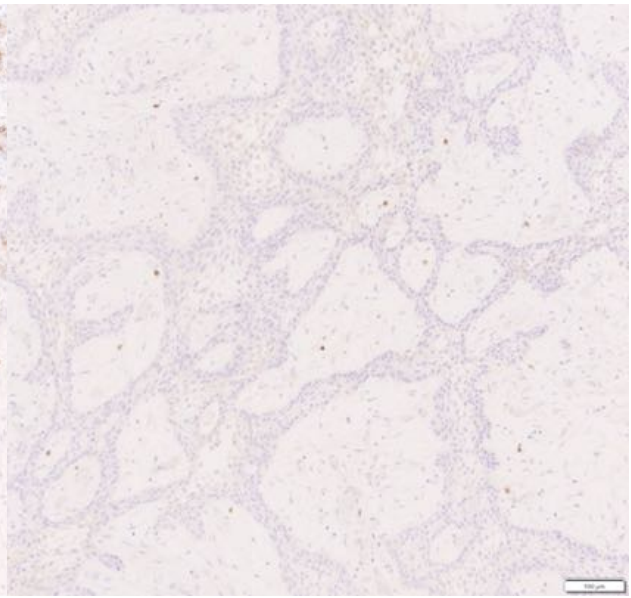

Calretinin

For Difficult Cases

- BRAF VE1: If positive, ameloblastoma with some certainty for <u>mandibular</u> tumors
  - BRAFV600E mutant ameloblastomas were positive by IHC in 18/19 (94.7%) cases and equivocal in 1/ 19 (5.3%) cases (Mendez et al. Mod Pathol 2022;35:1570)
  - BRAF-wild type ameloblastomas were negative by IHC (Mendez et al. Mod Pathol 2022;35:1570)
- CD56: If positive, ameloblastoma; if negative, ameloblastoma cannot be excluded
- Calretinin: We don’t use it anymore

Adenoid ameloblastoma: clinicopathologic description of five cases and systematic review of the current knowledge

Loyola AM, et al. Oral Surg Oral Med Oral Pathol Oral Radiol 2015;120:368-377

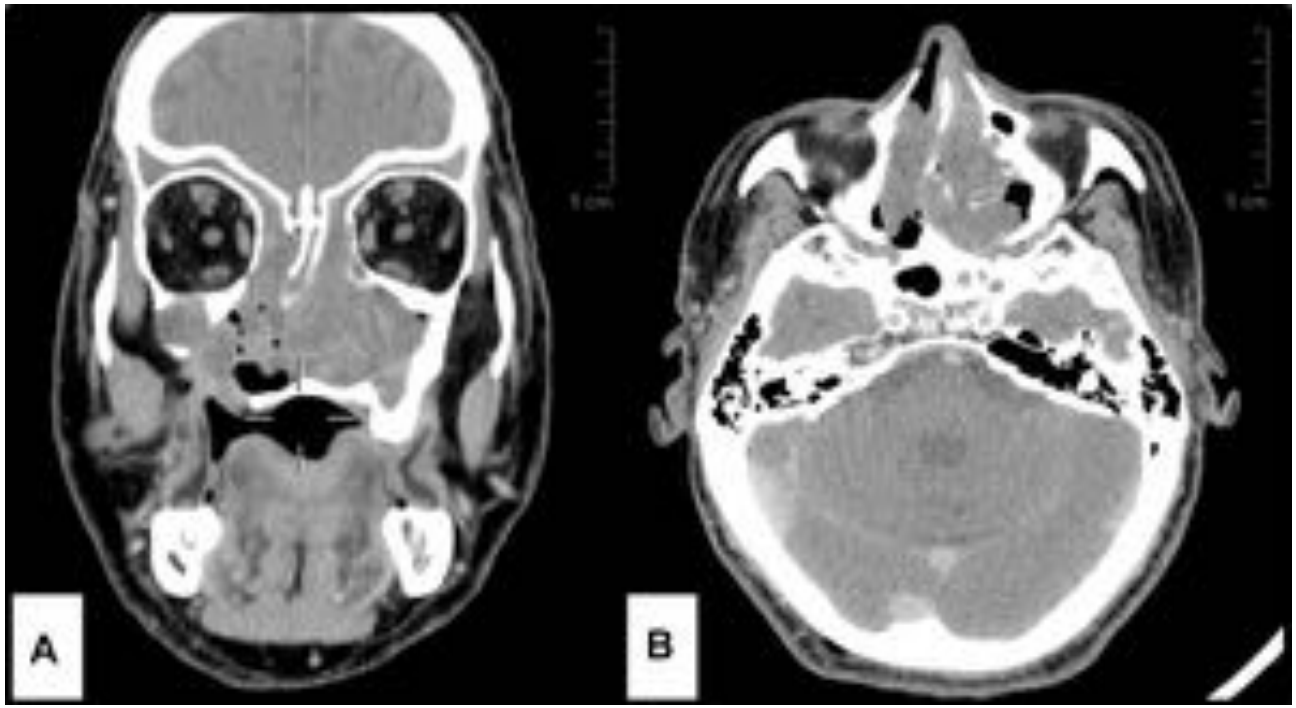

Adenoid ameloblastoma

- Very rare; maxilla
- M:F=1.5
- Conventional ameloblastoma
- Duct-like structures
- Clusters of clear cells
- Ghost-cell keratinization
- Calcifications, dentinoid
- CTNNB1 exon 3 mutations in 4/9 patients
  - β-catenin immunohistochemistry

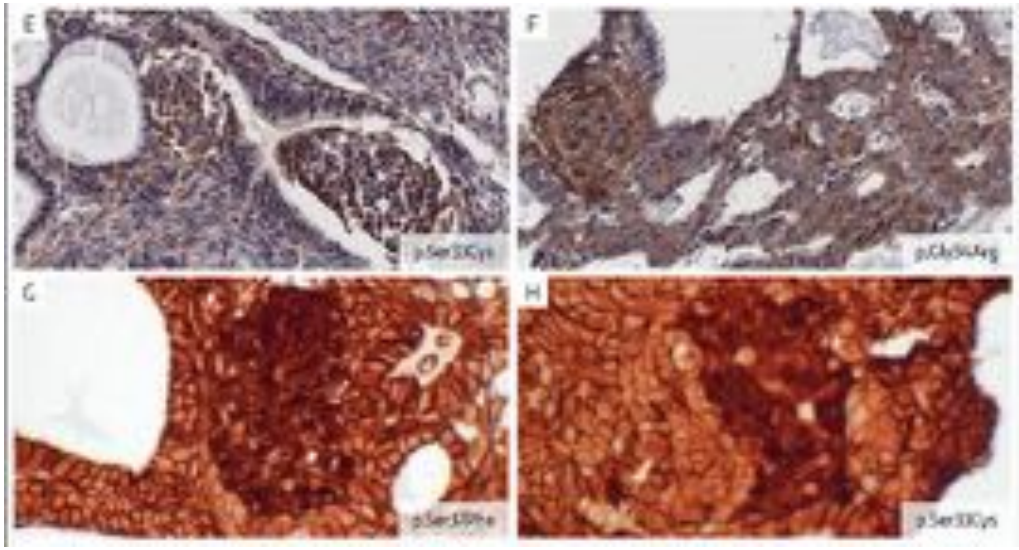

from Bastos et el. Mod Pathol 2022;35:1562

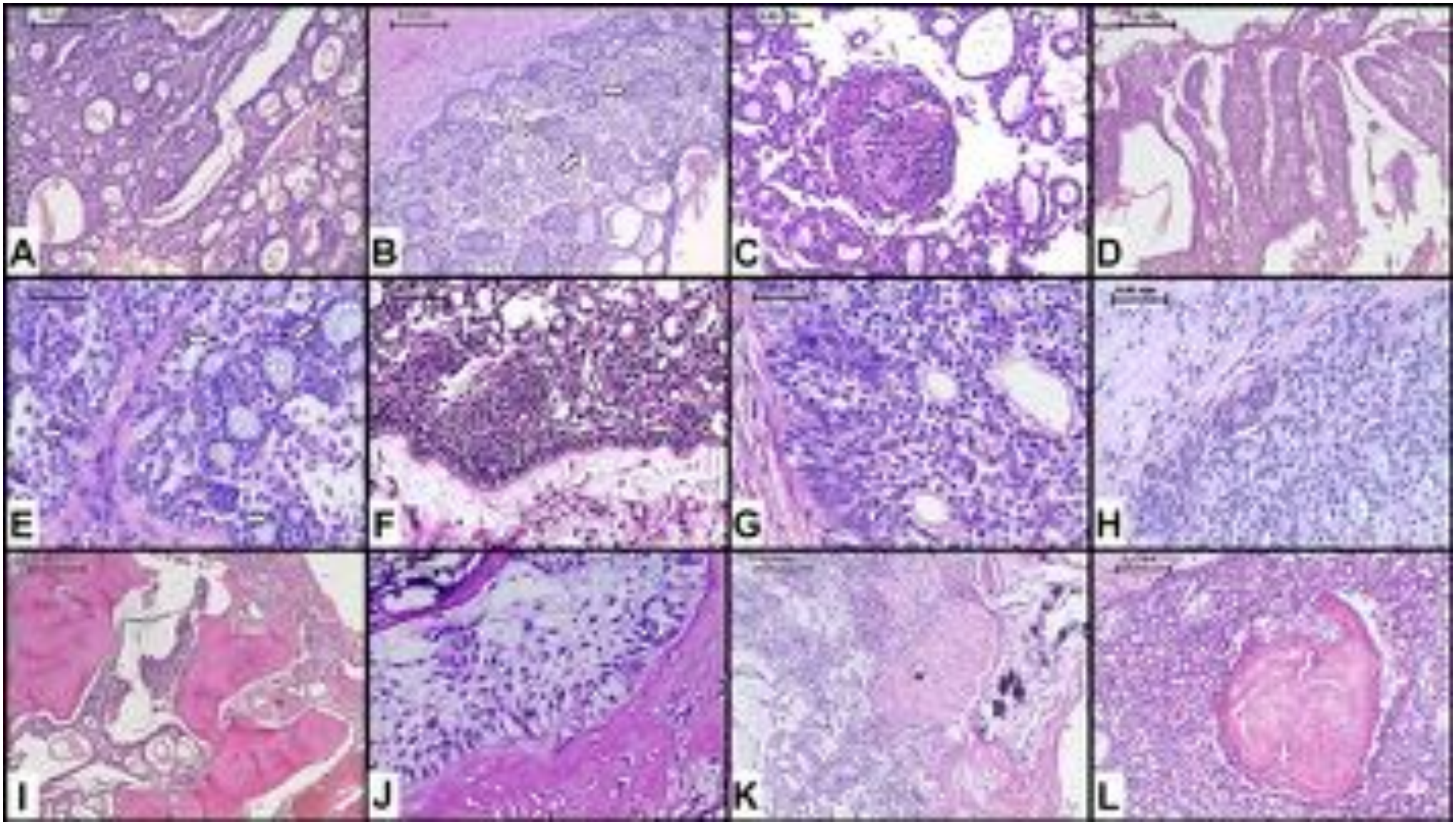
A
B
C
D
E
F
G
H
I
J
K
L

Pseudoducts in Adenoid Ameloblastoma

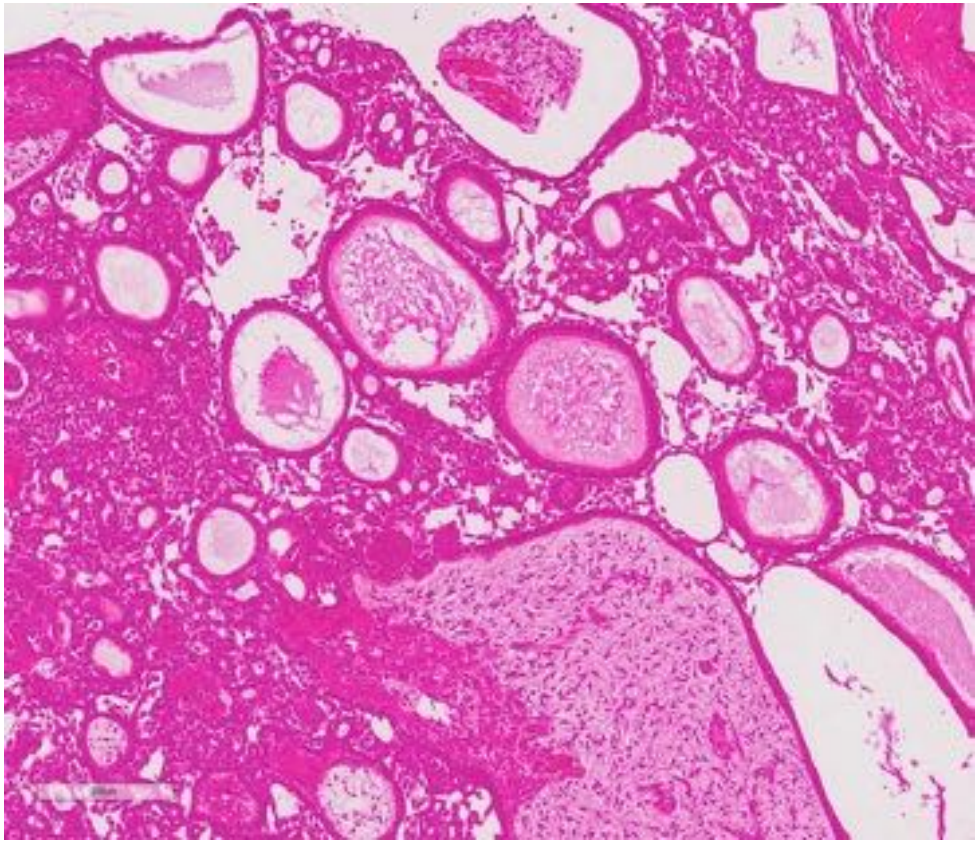

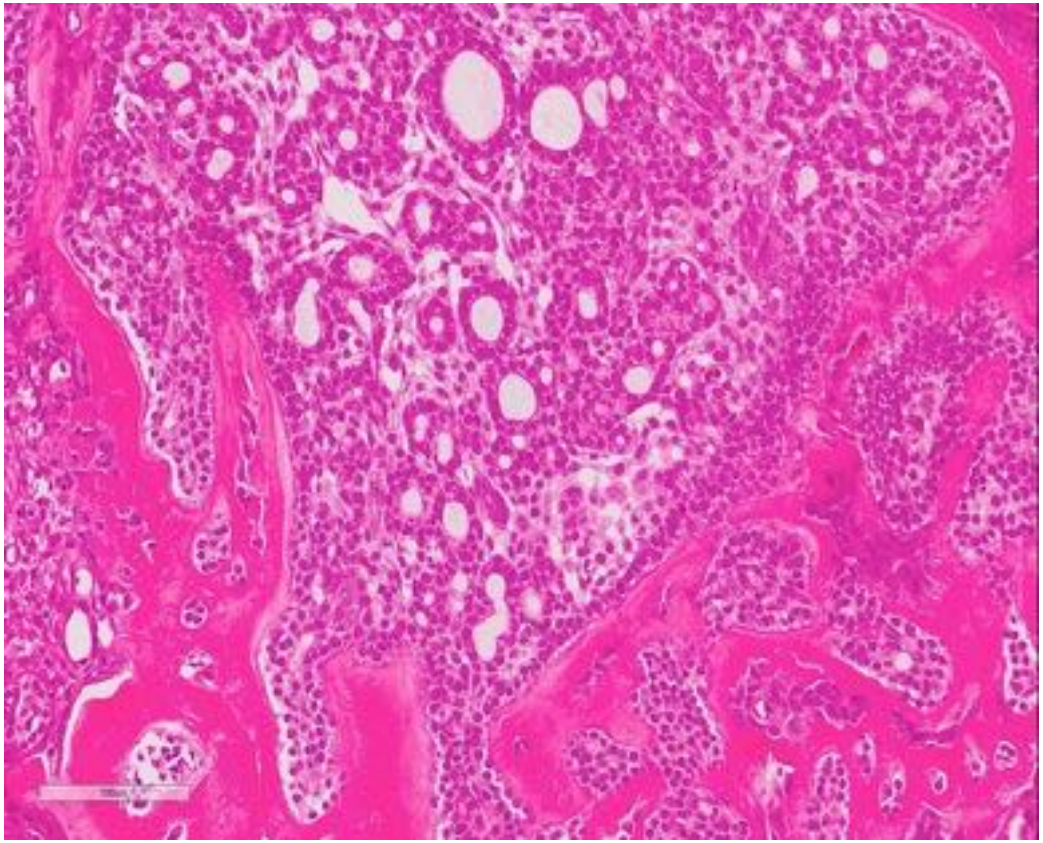

Primary Ameloblastoma of the Sinonasal Tract

- 19 males and 5 females
- Mean age 59.7 (43-81) years.
- Enlarging mass in the maxillary sinus or nasal cavity (n = 24)
  - Sinusitis (n = 9) or epistaxis (n = 8). Unilateral opacification of the maxillary sinus (n = 12) was the most common radiographic finding.
- Unilateral opacification of the maxillary sinus (n = 12)
- Characteristic features of ameloblastoma
  - The majority of the tumors showed a plexiform growth pattern. Fifteen tumors demonstrated surface epithelial derivation

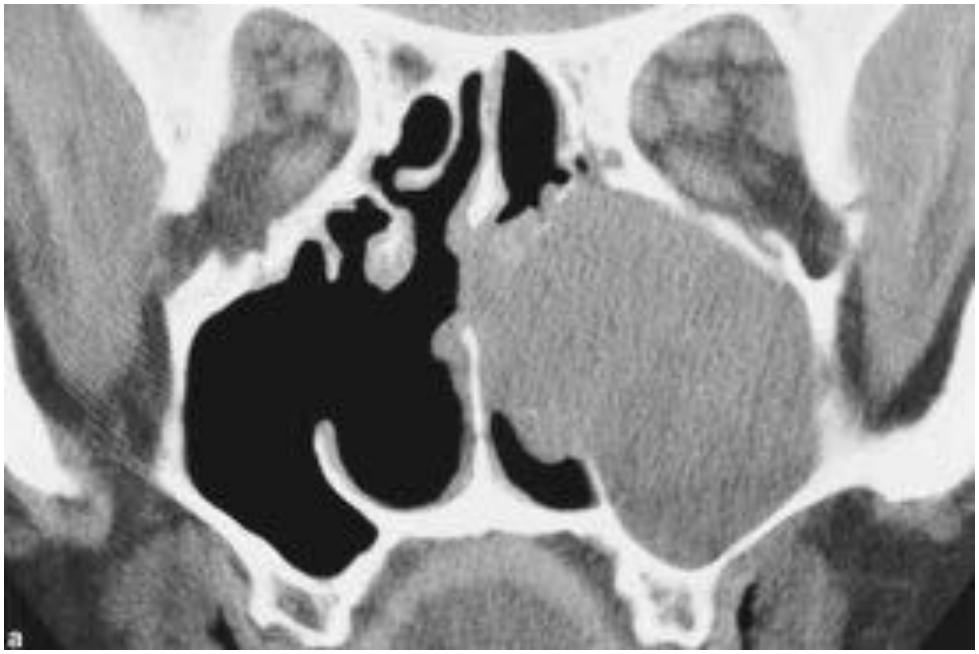

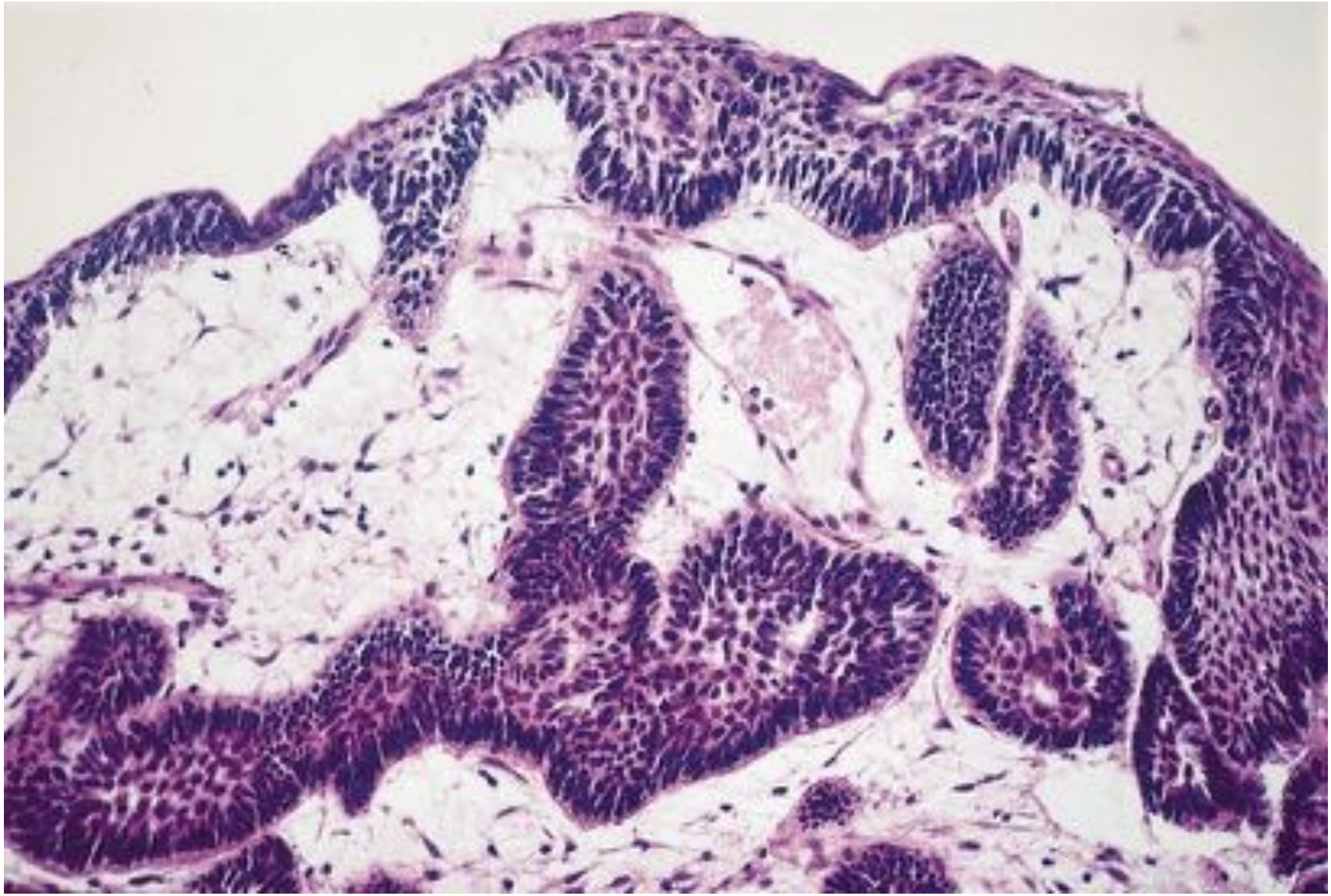

Keratoameloblastoma (KAB)

- NOT INCLUDED IN THE W.H.O.
- KAB/KOT-OKC features
- Scattered cystic and solid follicles
- Follicles showing extensive surface parakeratinization (Pacinian-like)
- Areas suggestive of KOT-OKC
- Hard tissue formation

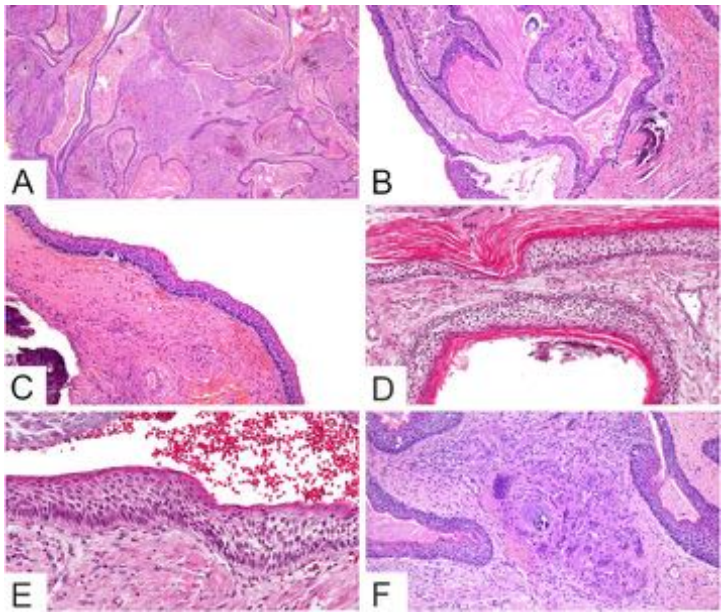

Robinson et al. Head Neck Pathol 2022; epub

Metastasizing ameloblastoma

- Included in the benign epithelial odontogenic neoplasms
  - 30% mortality rate
- Akin to behavior of metastasizing pleomorphic adenoma?

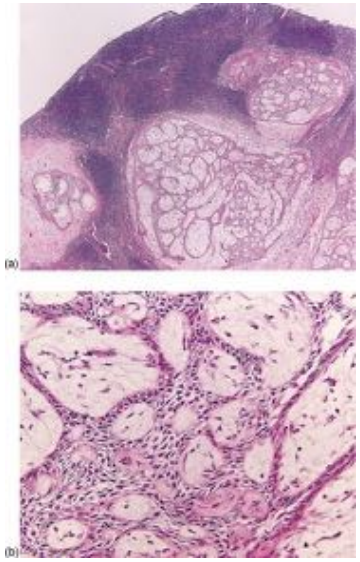

Adenomatoid odontogenic tumor (AoT)

- Adenoameloblastoma (No-one uses this term)
- Kras mutations in ½ cases
- Hamartoma
- Possible induction of ectomesenchyme (dentinoid)
- Maxilla
- Patients between 10-19 years old
- 2F:M
- Enucleation

Adenomatoid odontogenic tumor

- *KRAS* (mitogen activating protein kinase, MAPK, pathway; p.G12V and p.G12R loci) in 70 % of the cases
- Multiple in patients with Schimmelpenning syndrome caused by postzygotic mutations in *RAS*.

Adenomatoid odontogenic tumor

- Solid or cystic
- Spindle-shaped epithelial cells
- Whorls or strands
- Rosette-like structures
- Tubular or duct-like structures (may not be present; not true ducts)
- Calcifications
  - Abortive enamel
  - Dentinoid or cementum

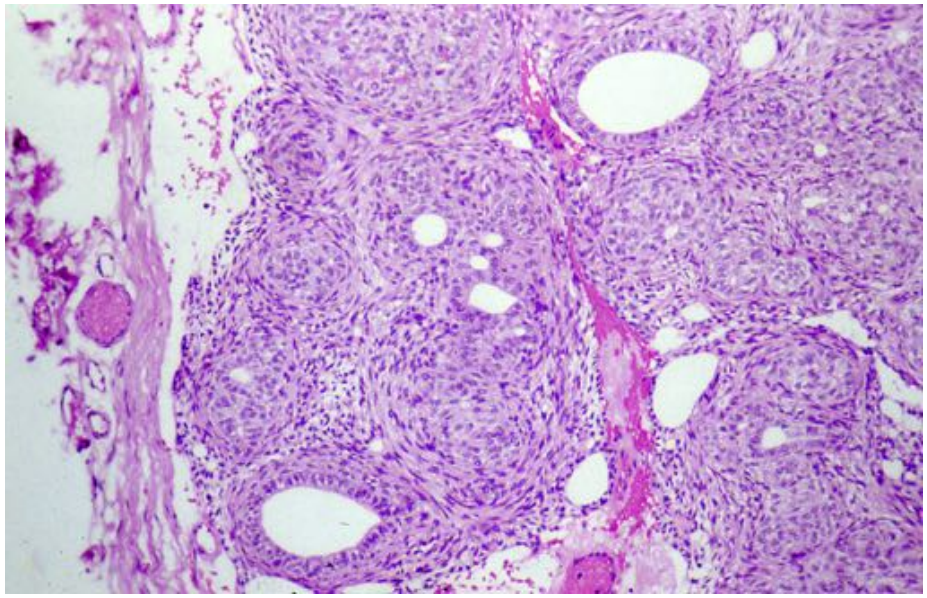

Calcifying epithelial odontogenic tumor

- 30-50 years of age
- 2/3 in posterior mandible
  - Association with impacted molar
- Rare peripheral examples
- Unilocular or multilocular radiolucency with sometimes radiopaque areas
- Less aggressive than ameloblastoma
- Conventional
- Cystic or microcystic type
  - Gopalakrishnan et al. 4OE 2006;102:773-7
- Non-calcifying with Langerhans' cells (NCLC)
  - I do NOT agree
  - Central odontogenic fibroma with amyloid (COF)
  - NCLC has essentially similar clinical presentation with COF

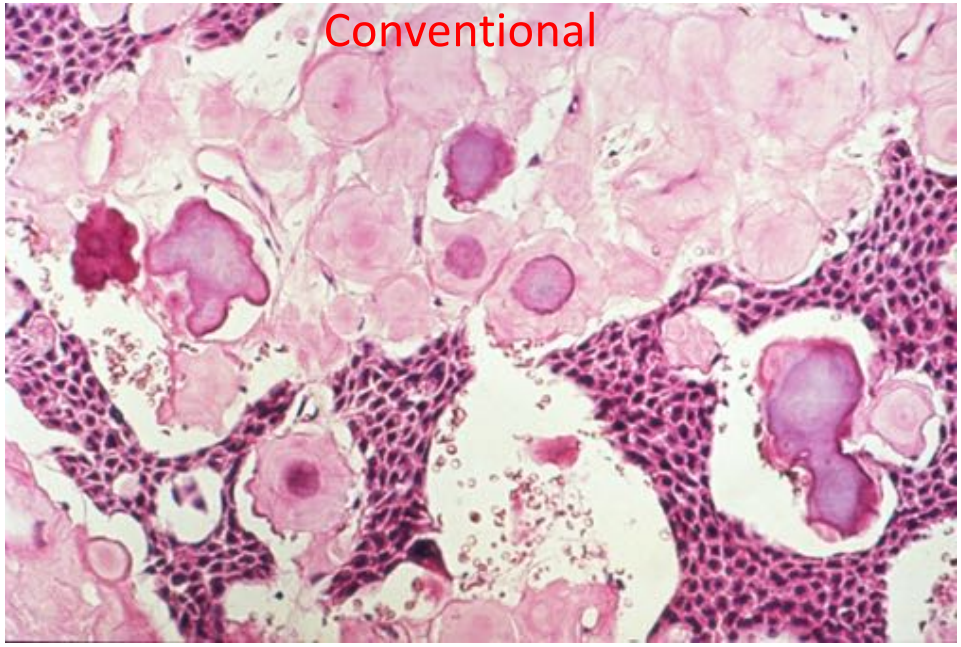

Cystic or microcystic type

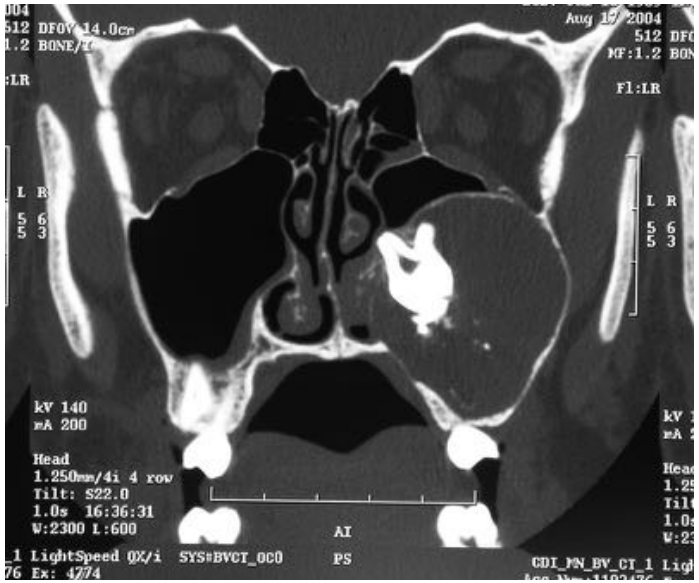

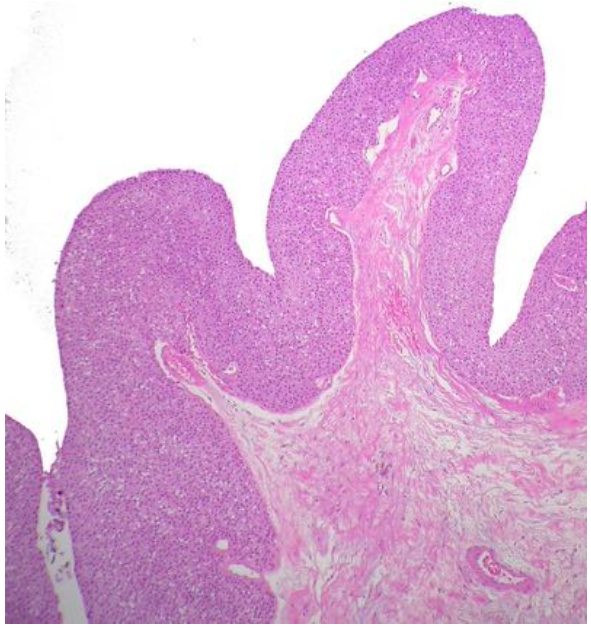

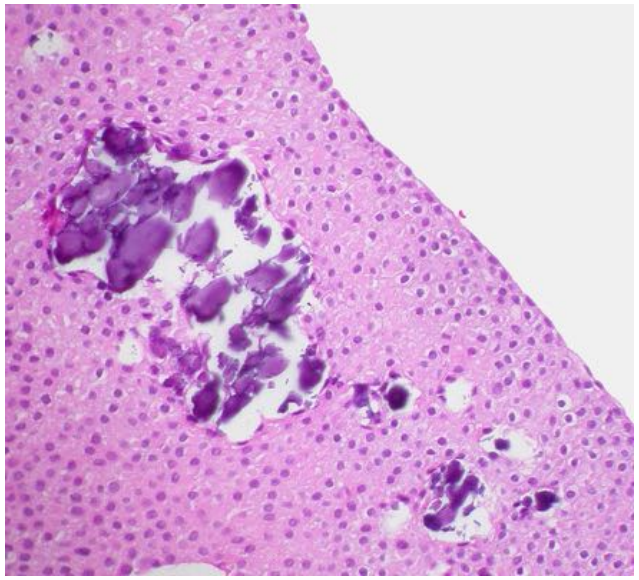

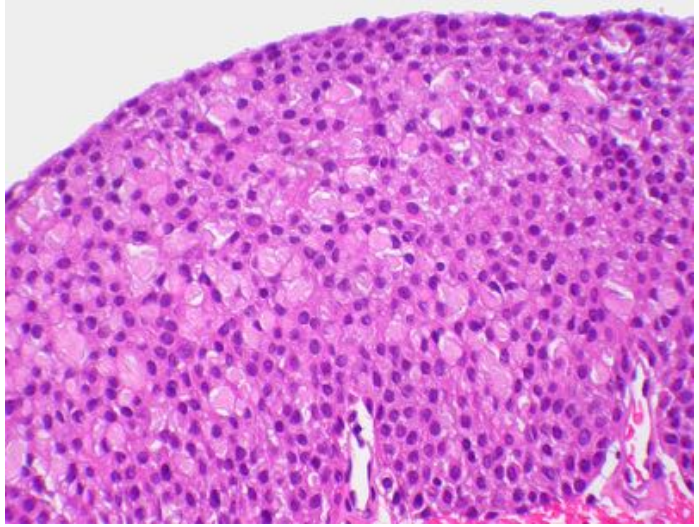

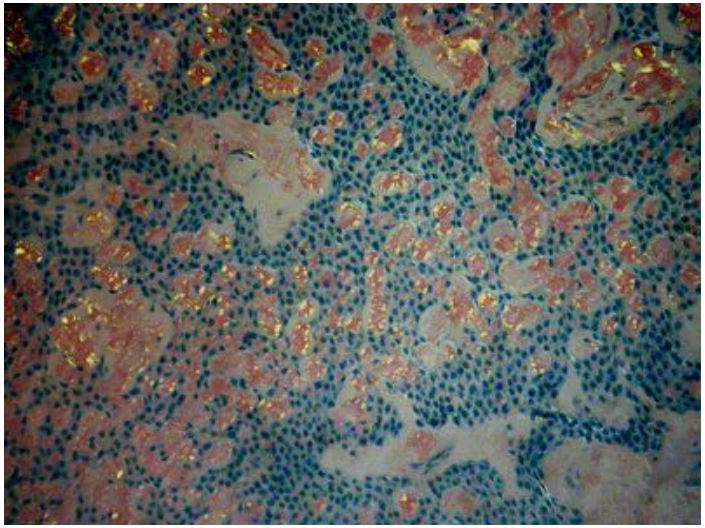

Non-calcifying variant with Langerhans' cells variant (NOT IN MY OPINION)

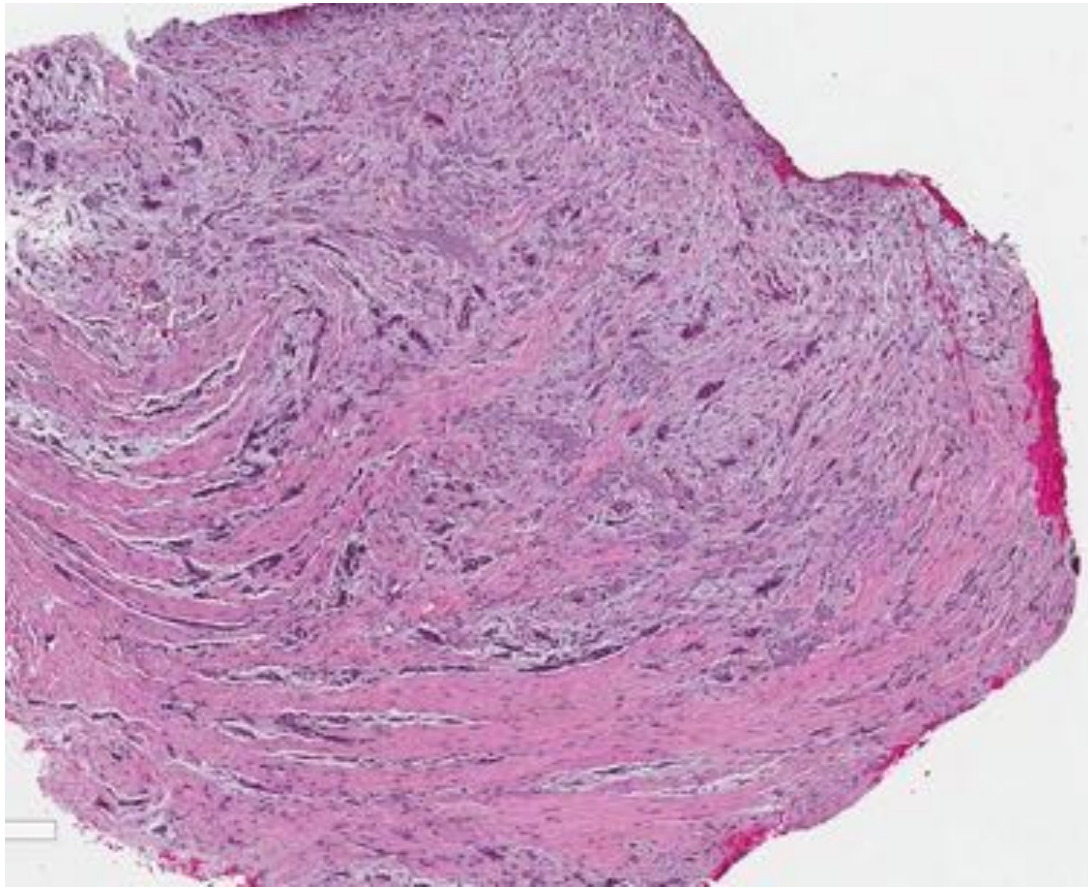

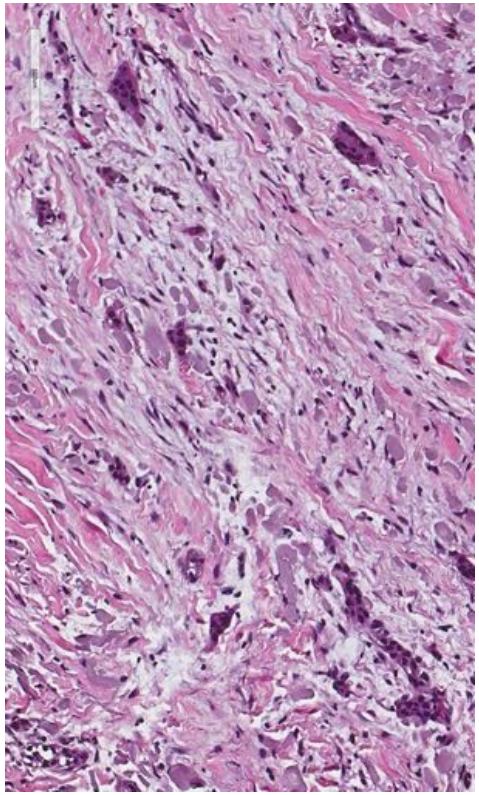

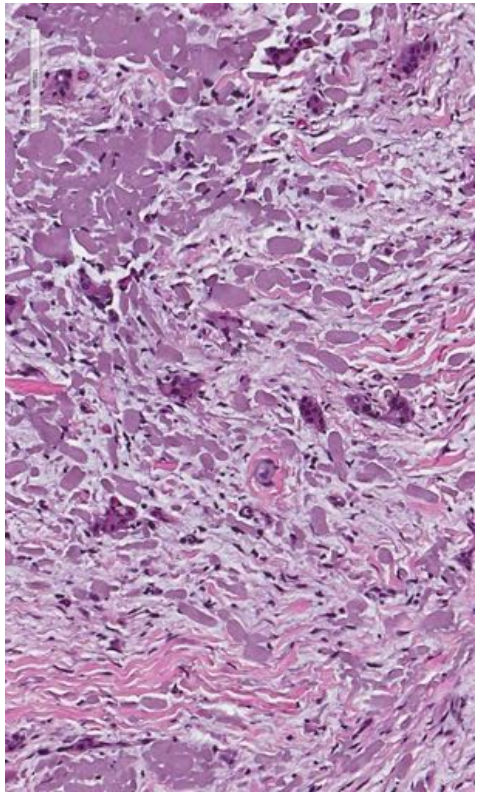

Non-calcifying variant with Langerhans' cells variant (NOT IN MY OPINION)

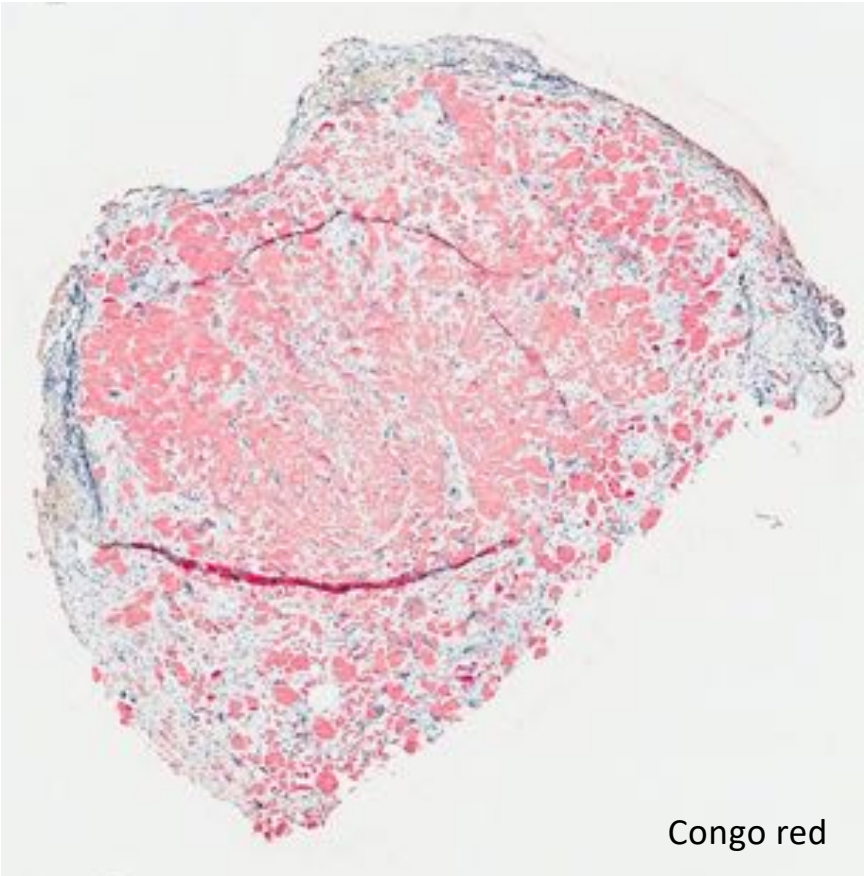

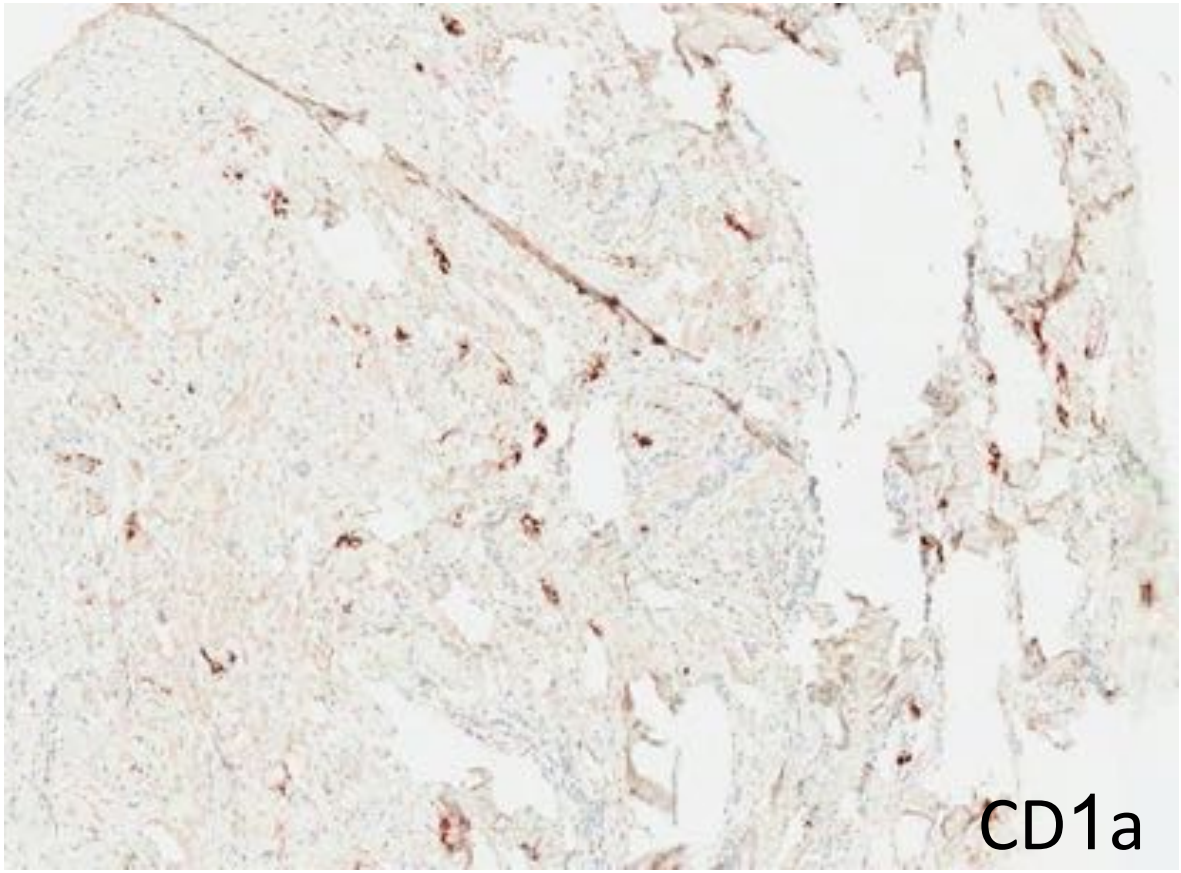

Odontomas

- Hamartomas
- Aberrant activation of the Wnt/β-catenin signaling
- Decreased Sema3A expression

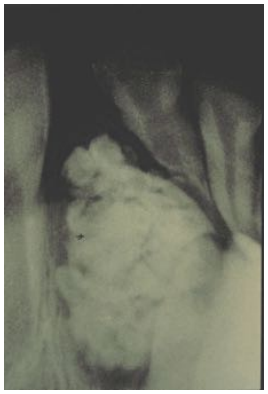

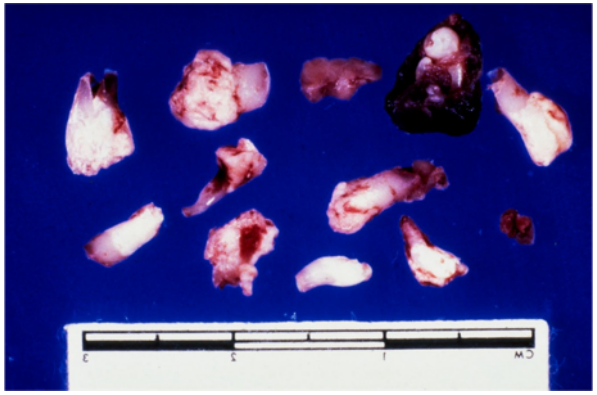

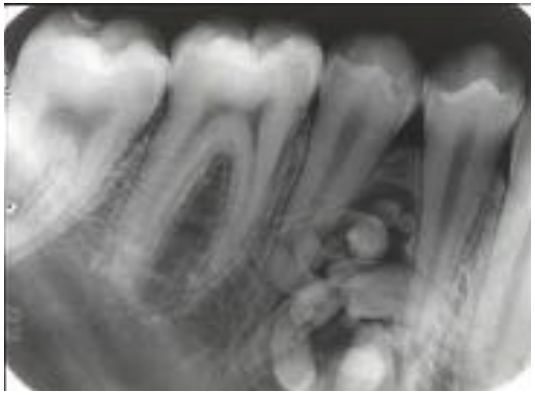

Benign mixed epithelial and mesenchymal odontogenic tumors (2022)	Benign mixed epithelial and mesenchymal odontogenic tumors (2017)
Odontoma	Ameloblastic fibroma
Primordial odontogenic tumour	Primordial odontogenic tumour
Ameloblastic fibroma	Odontoma
Dentinogenic ghost tumour	-Odontoma, compound type
	-Odontoma, complex type
	Dentinogenic ghost tumour

BRAF IN MIXED ODONTOGENIC TUMORS

- BRAF p.V600E in a subset
  - Ameloblastic fibroma
  - Ameloblastic fibrodentinoma
  - Ameloblastic fibro-odontoma
  - Ameloblastic fibrosarcoma
- BRAF wild type
  - Odontomas

Primordial odontogenic tumor

- Children and young patients
- 6Man:Max
- Association with unerupted teeth (wisdom)
- Asymptomatic
- Cortical expansion

A 19-year-old man had a painless incidental finding

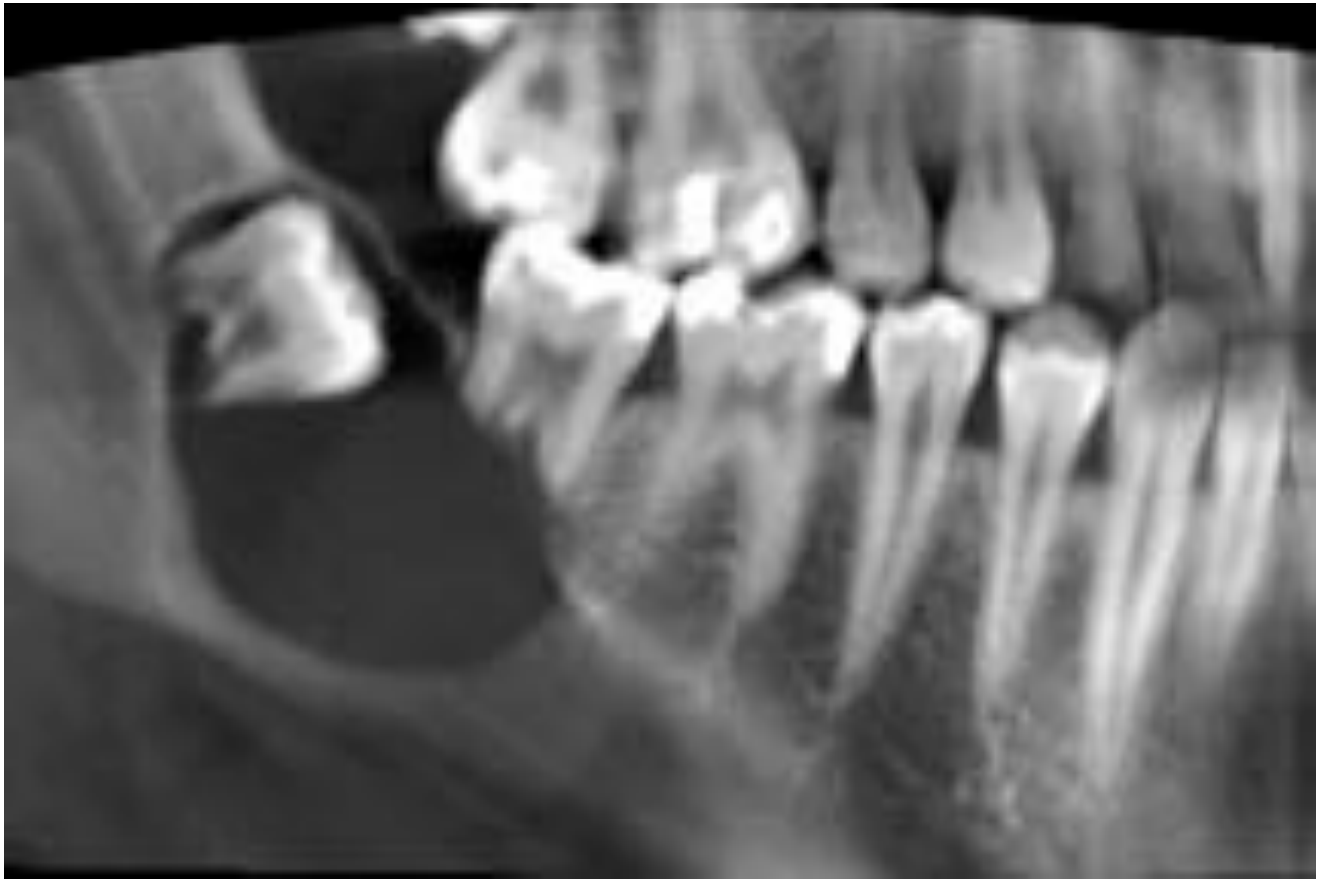

Courtesy of Dr. Lee Slater

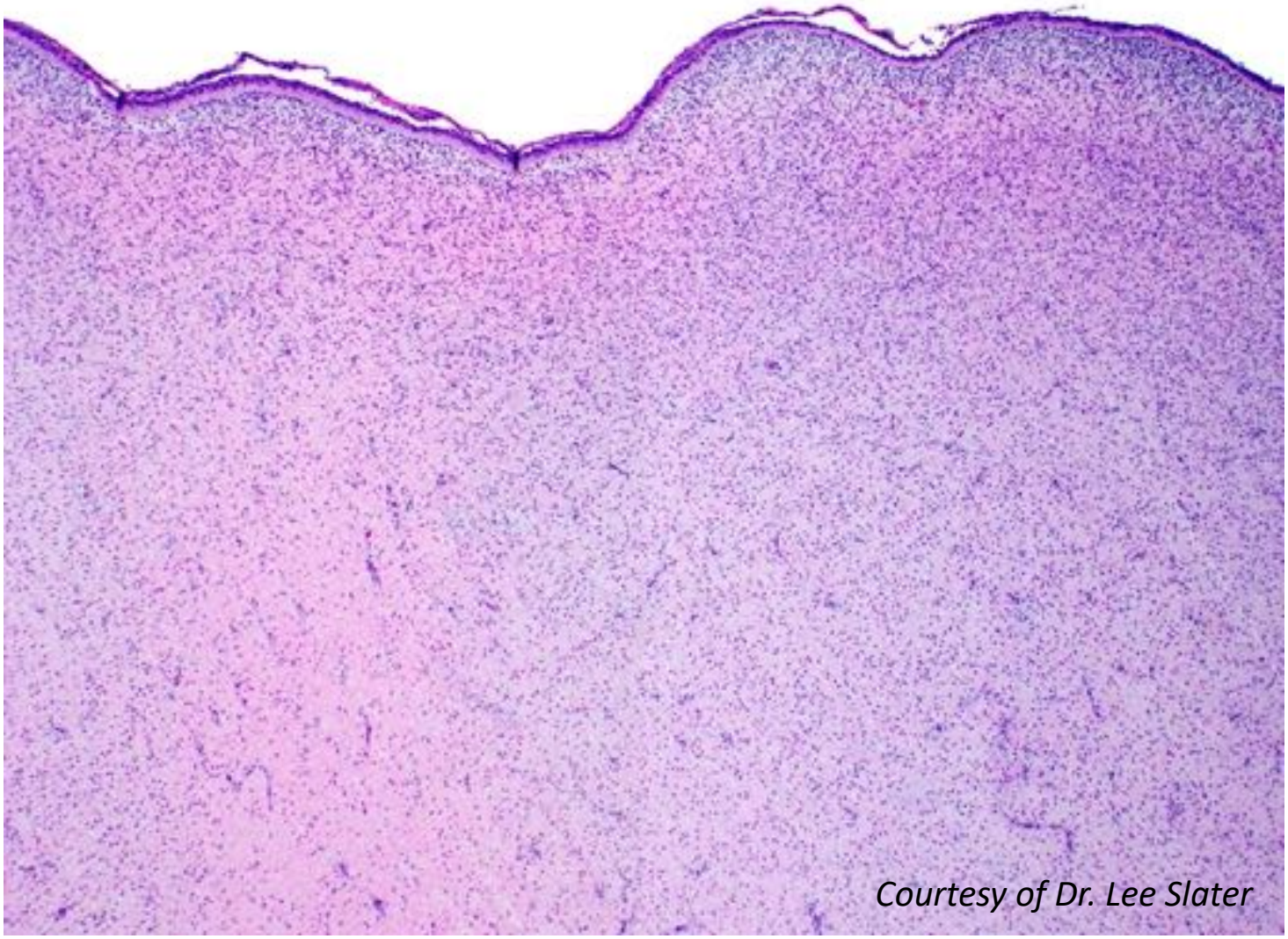
Courtesy of Dr. Lee Slater

Primordial odontogenic tumor

- Variably cellular loose fibrous connective tissue
- Areas similar to dental papilla
- Surrounded by cuboidal and columnar cells resembling the inner enamel epithelium

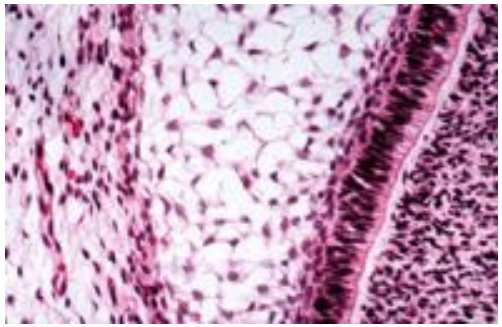

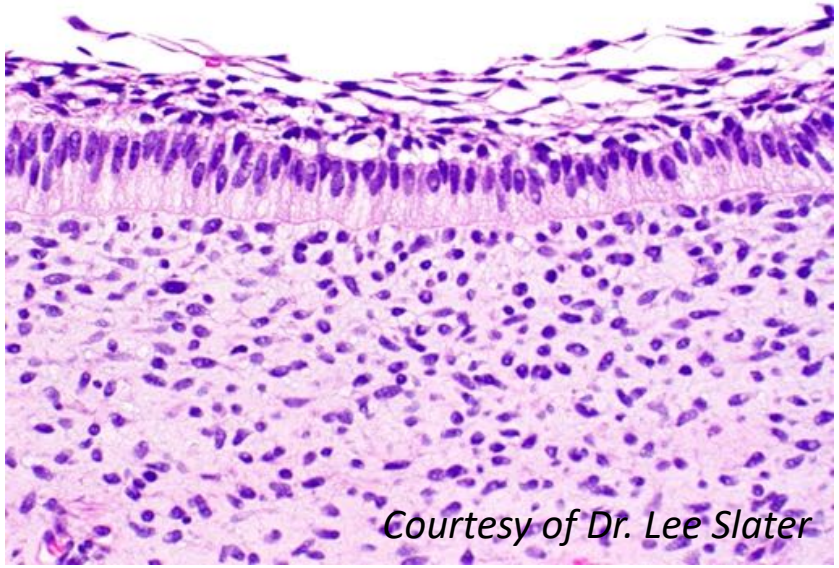

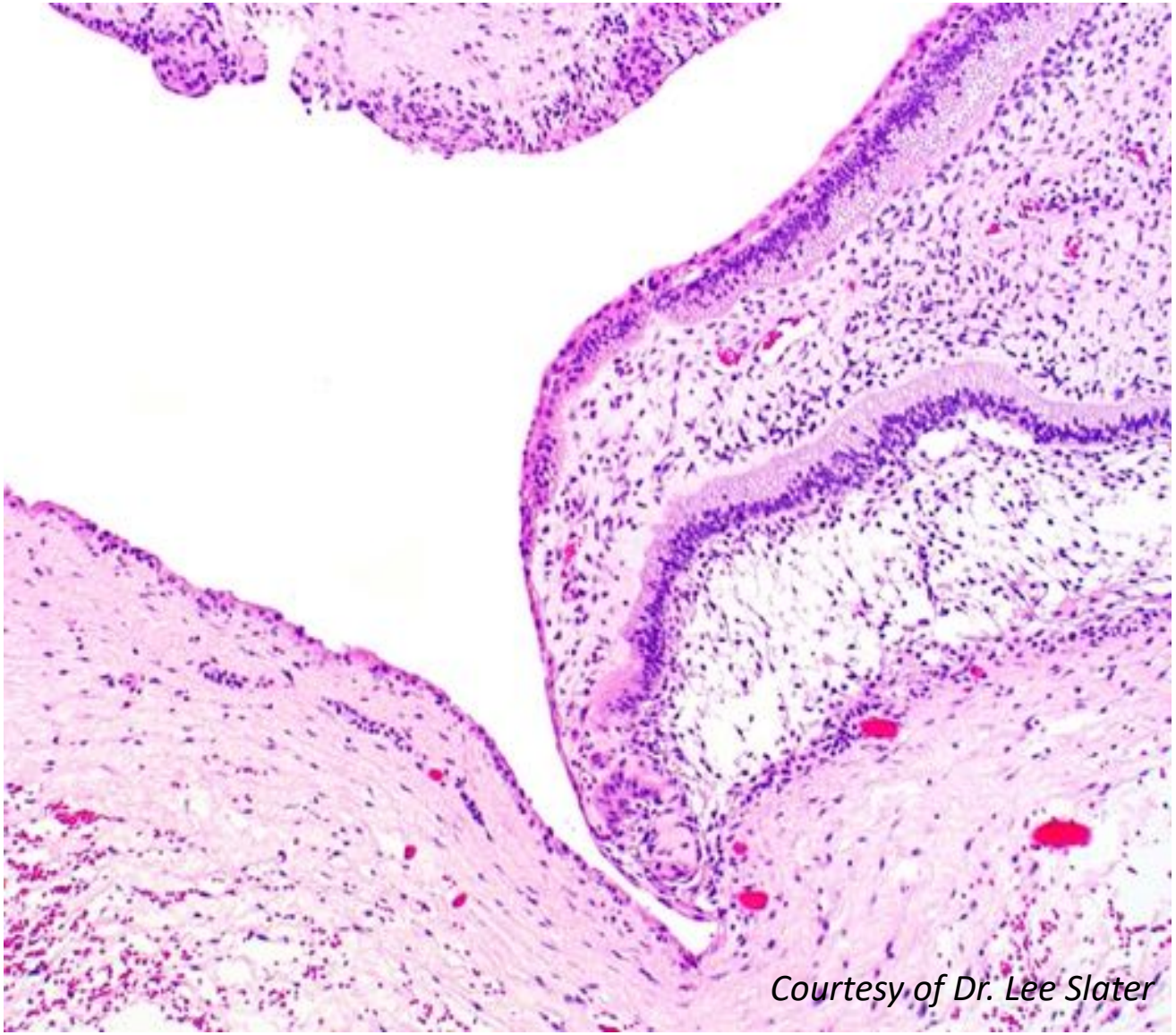
Courtesy of Dr. Lee Slater

Benign mesenchymal odontogenic tumors (2022)	Benign mesenchymal odontogenic tumors (2017)
Odontogenic fibroma	Odontogenic fibroma
Cementoblastoma (osteoblastoma)	Odontogenic myxoma/myxofibroma
Cemento-ossifying fibroma	Cementoblastoma
Odontogenic myxoma	Cemento-ossifying fibroma (benign fibro-osseous lesions)

Malignant odontogenic tumors (2022)	**Malignant odontogenic tumors (2017)**
Sclerosing odontogenic carcinoma	Ameloblastic carcinoma
Ameloblastic carcinoma	Primary intraosseous carcinoma, NOS
Clear cell odontogenic carcinoma	Sclerosing odontogenic carcinoma
Ghost cell odontogenic carcinoma	Clear cell odontogenic carcinoma
Primary intraosseous carcinoma, NOS	Ghost cell odontogenic carcinoma
Odontogenic carcinosarcoma	Odontogenic carcinosarcoma
Odontogenic sarcomas	Odontogenic sarcomas

Primary intraosseous carcinoma

Primary intraosseous SCC- solid

Primary intraosseous SCC- from KCOT

Primary intraosseous SCC- from odontogenic cyst

Sclerosing Odontogenic Carcinoma

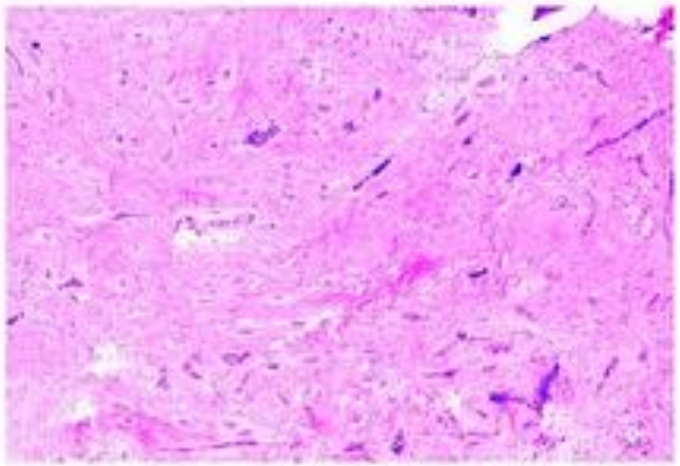

FIGURE 4. Prominent sclerosis with few scattered neoplastic nests (patient 3).

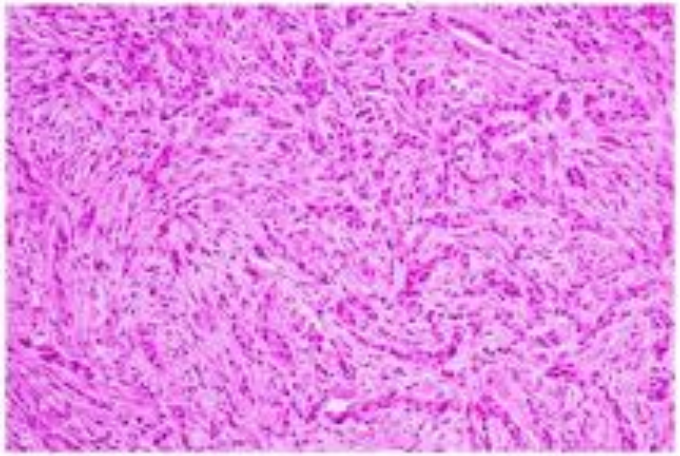

FIGURE 6. Infiltrating cords of neoplastic epithelial cells show some of them exhibiting mild pleomorphism and nuclear hyperchromatism. Mitotic activity was extremely rare.

AJSP 2008; 32:1613-19

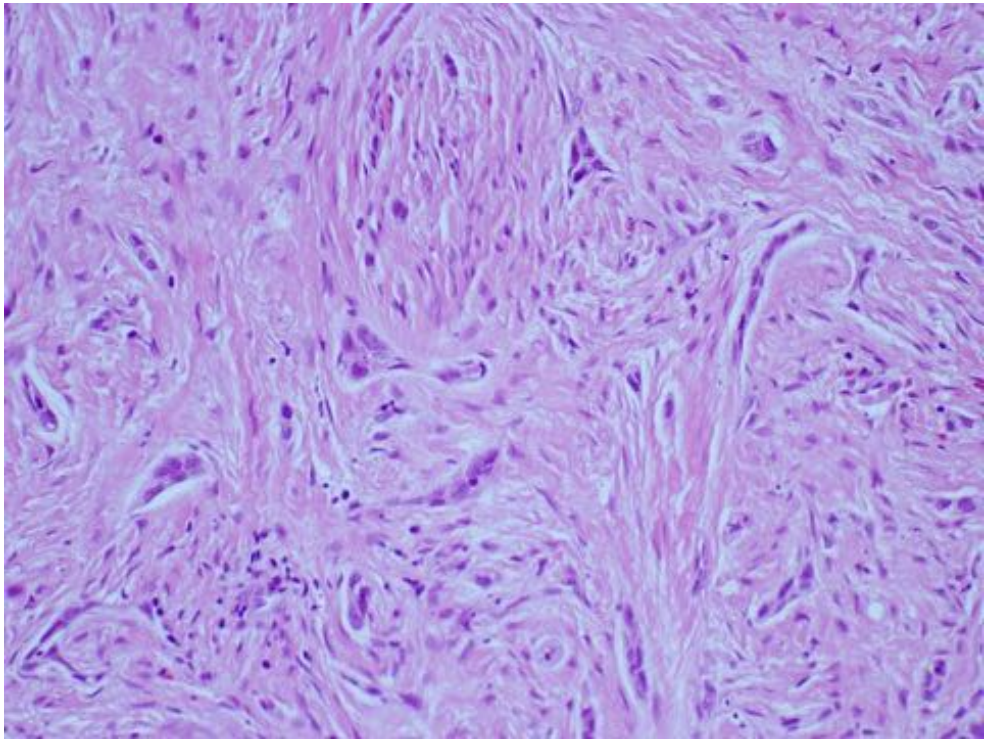

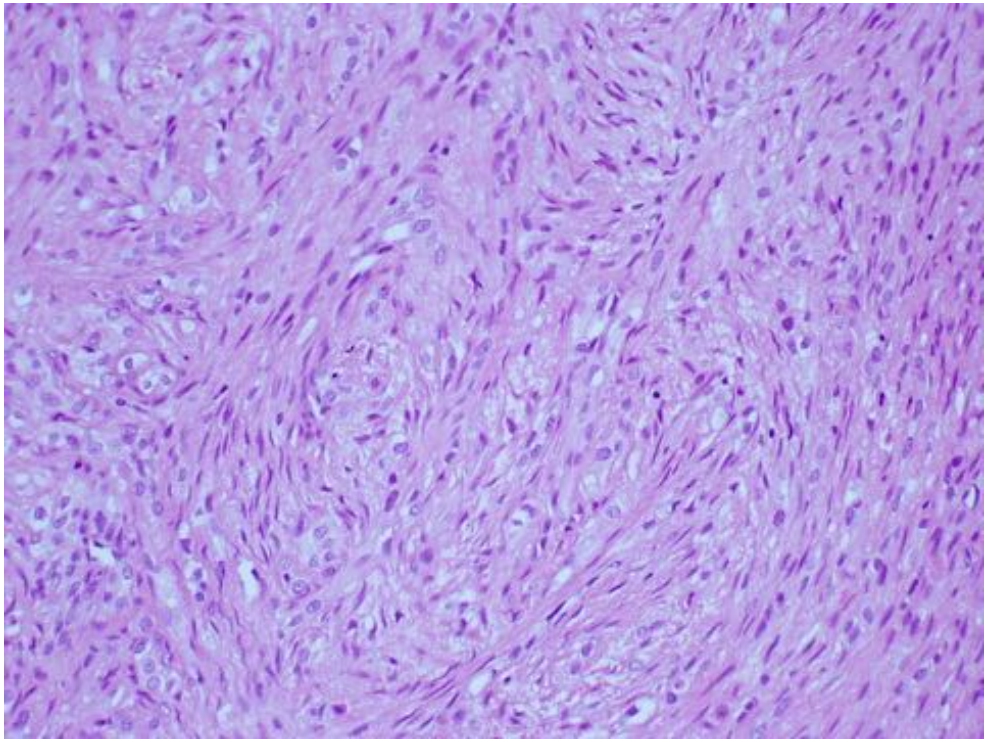

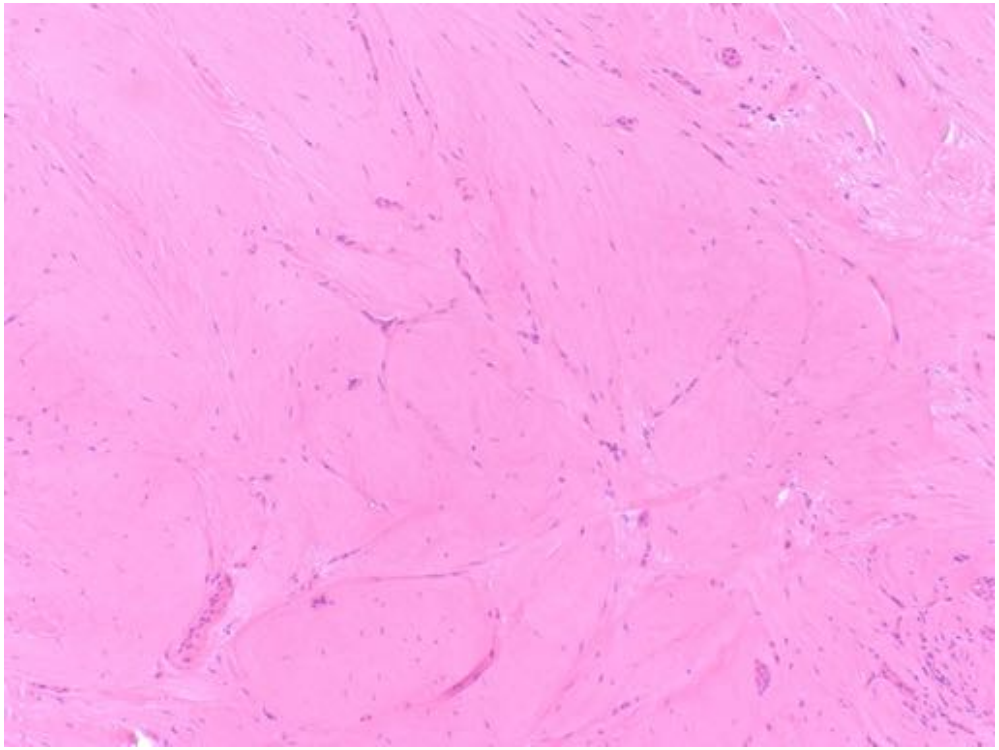

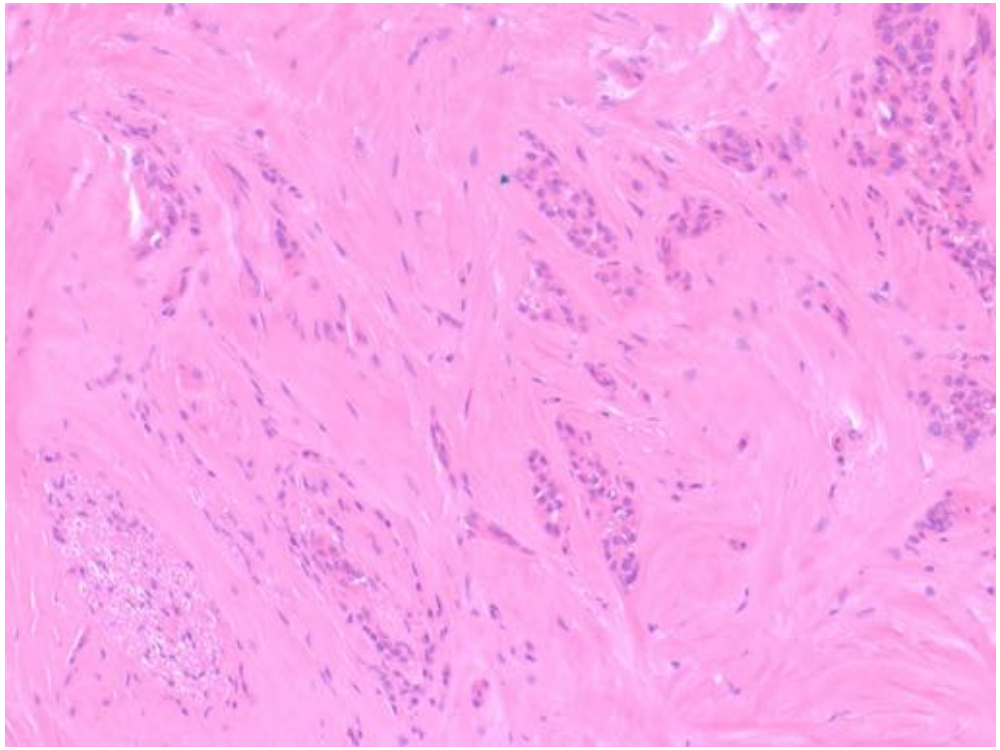

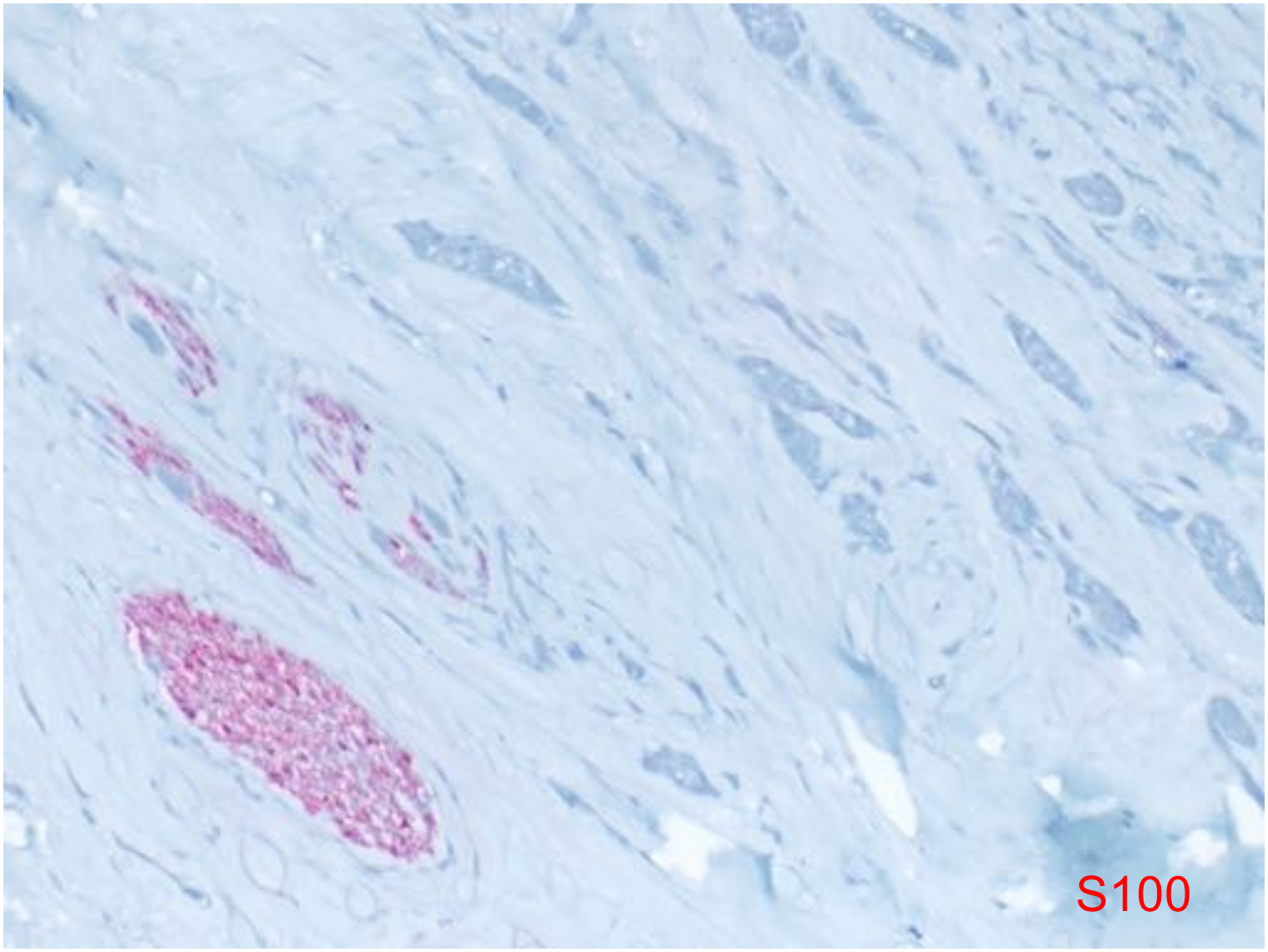
S100

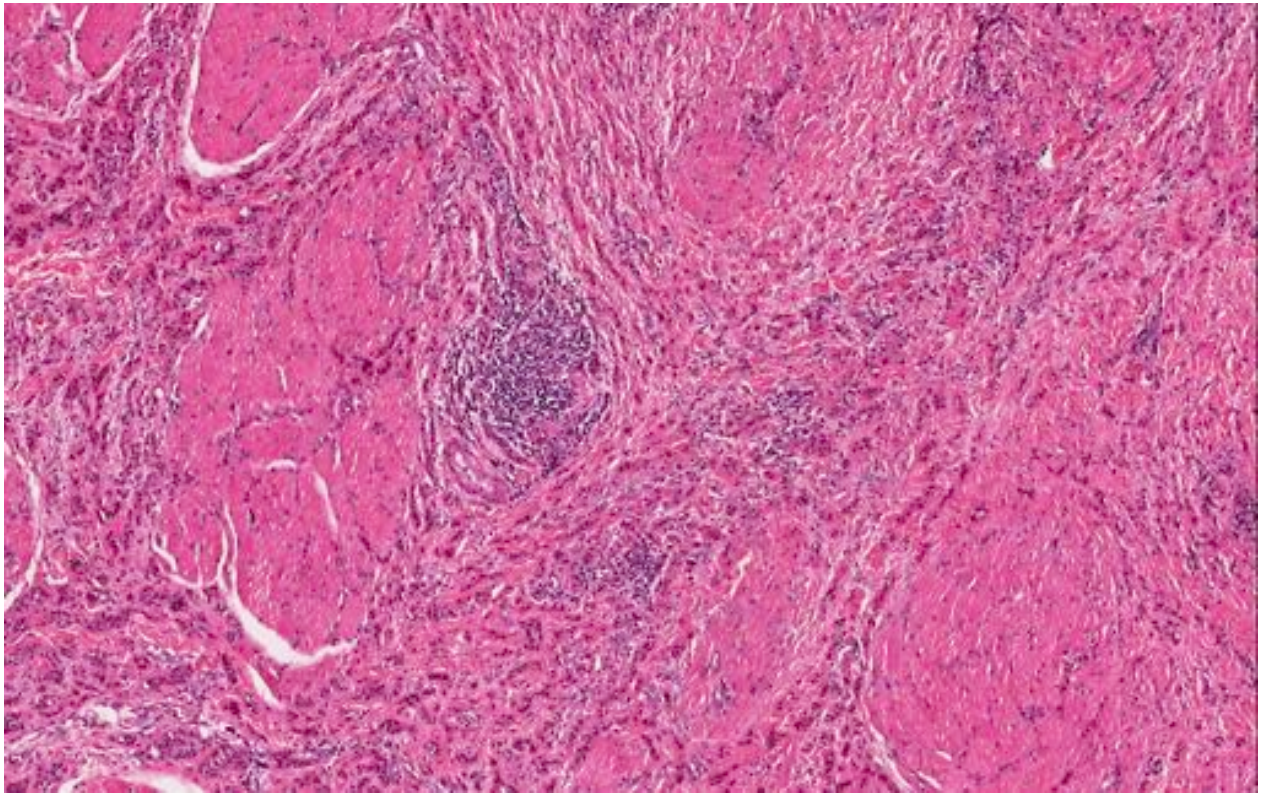

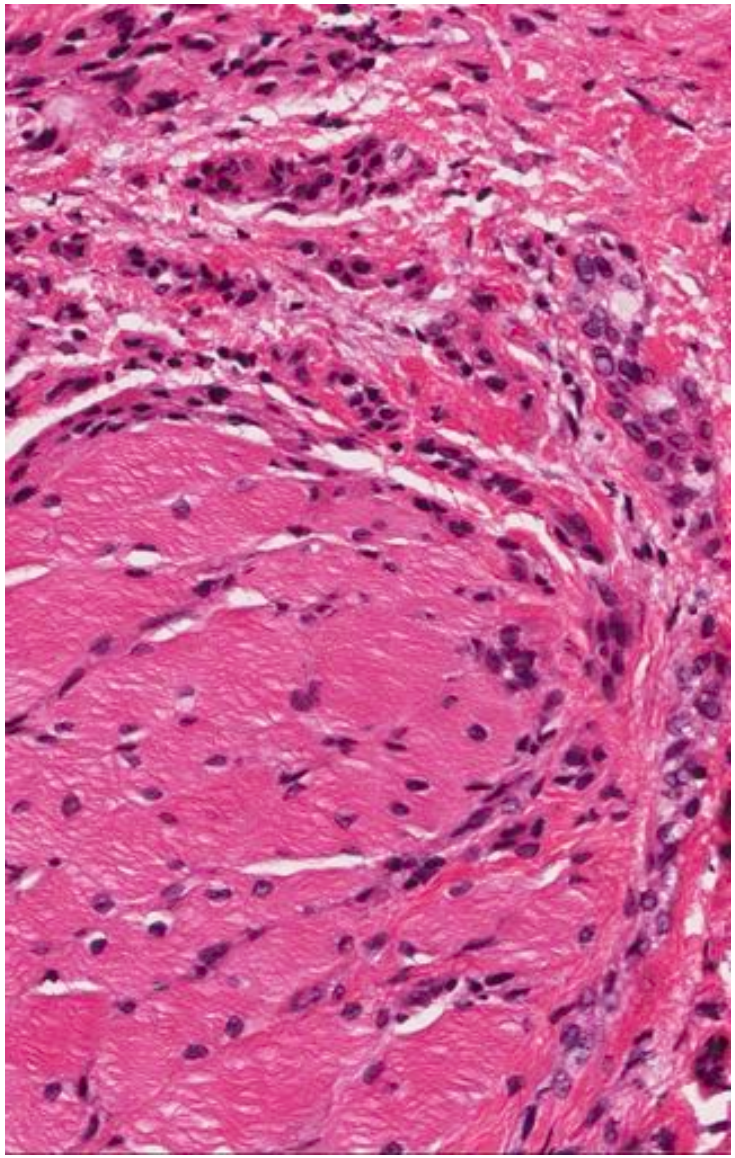

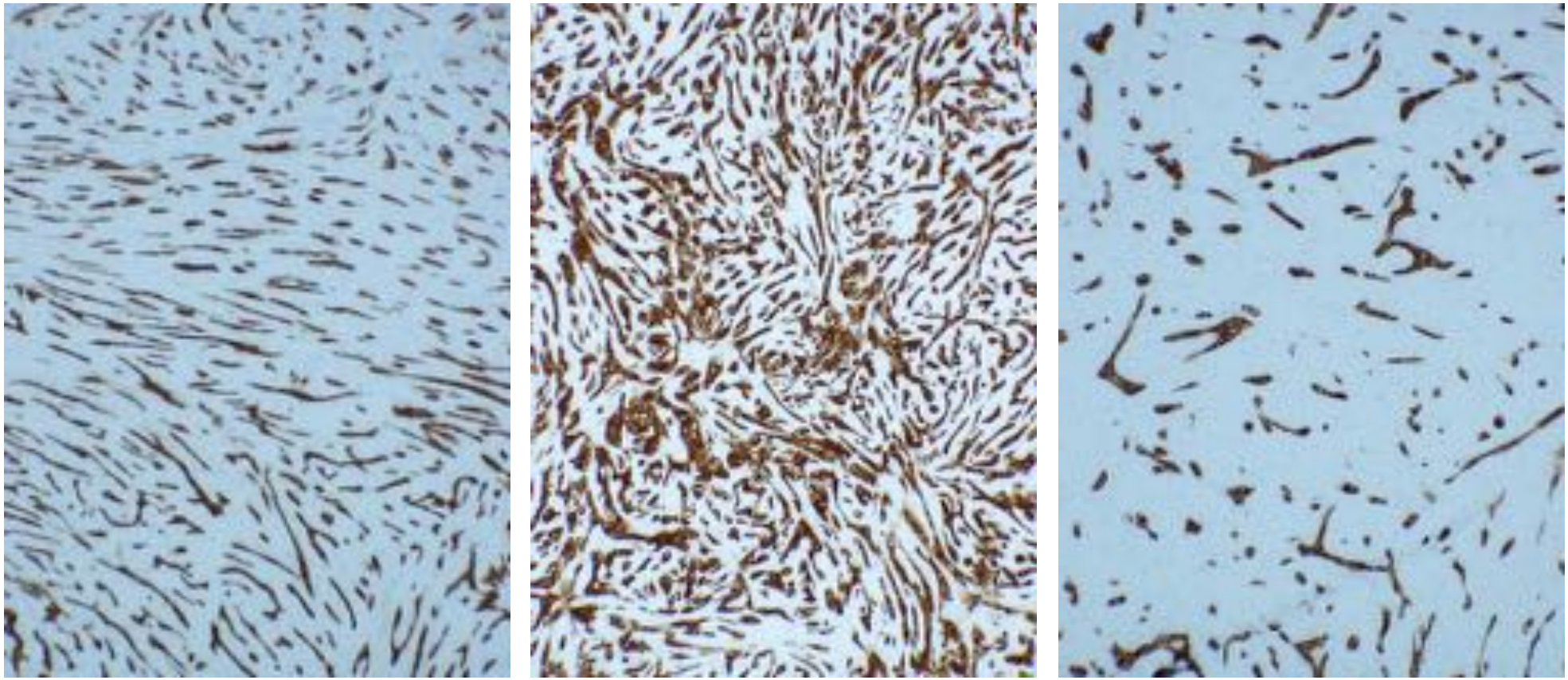

CK19

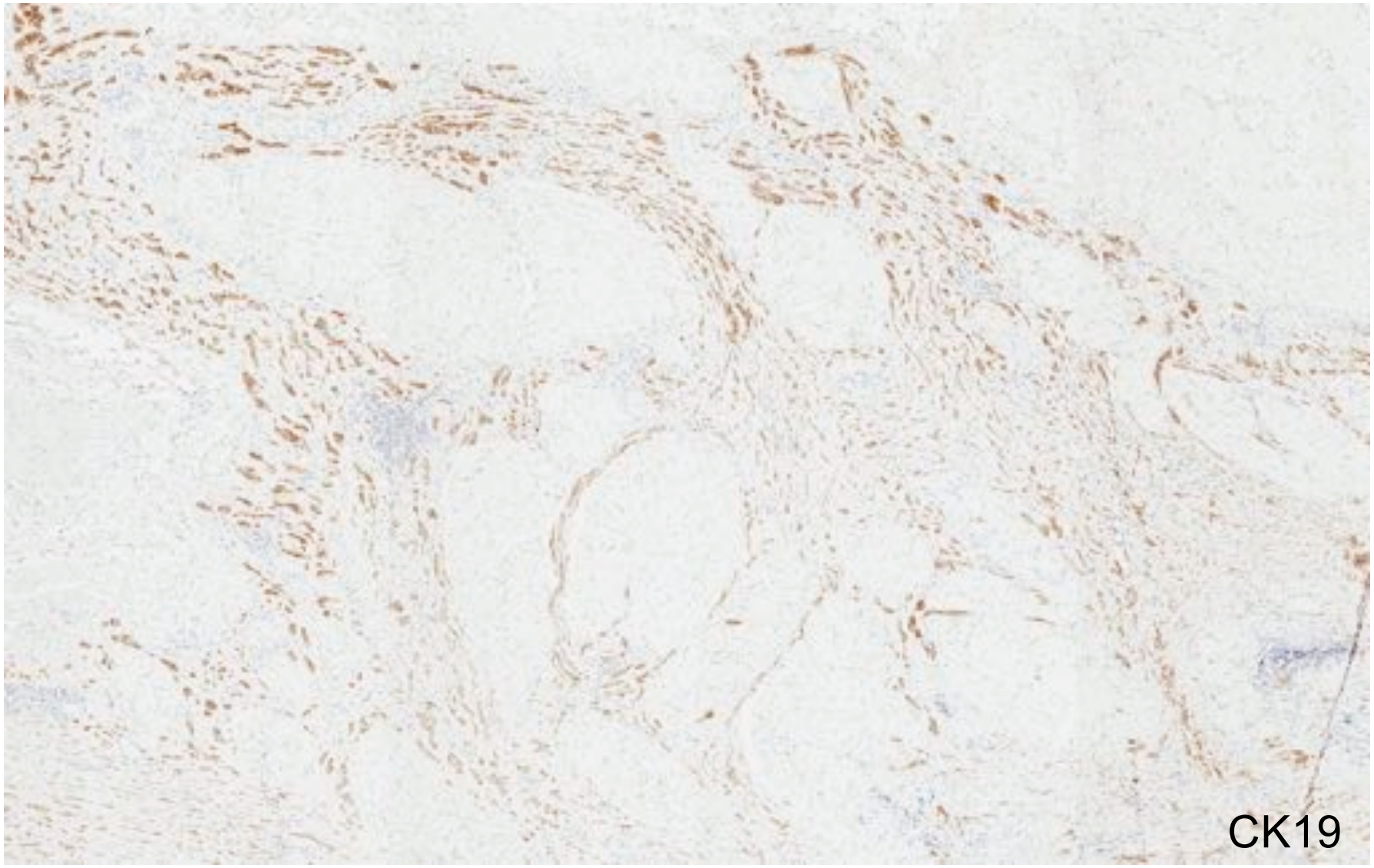
CK19

My opinion

- Diagnosis of exclusion ?
- Difficult diagnosis, even impossible with small (incisional) biopsy
- Well documented infiltration of nerves and skeletal muscle
- Tumor vs. carcinoma
- What should you tell to the surgeon ?
- Does it belong to the new classification ?

Odontogenic Carcinoma with Dentinoid

- 9 reported examples
- Spectrum of histopathological features composed predominantly of clear cells with variable amounts of small round to basaloid cells with more accentuated pleomorphism.
- In some cases, there may be duct-like or pseudocystic structures, peripheral columnar cells with evidence of palisading and, as described in one case, scattered ghost cells
  - vs. adenoid ameloblastoma
- 2mand:max
- 5M:4F

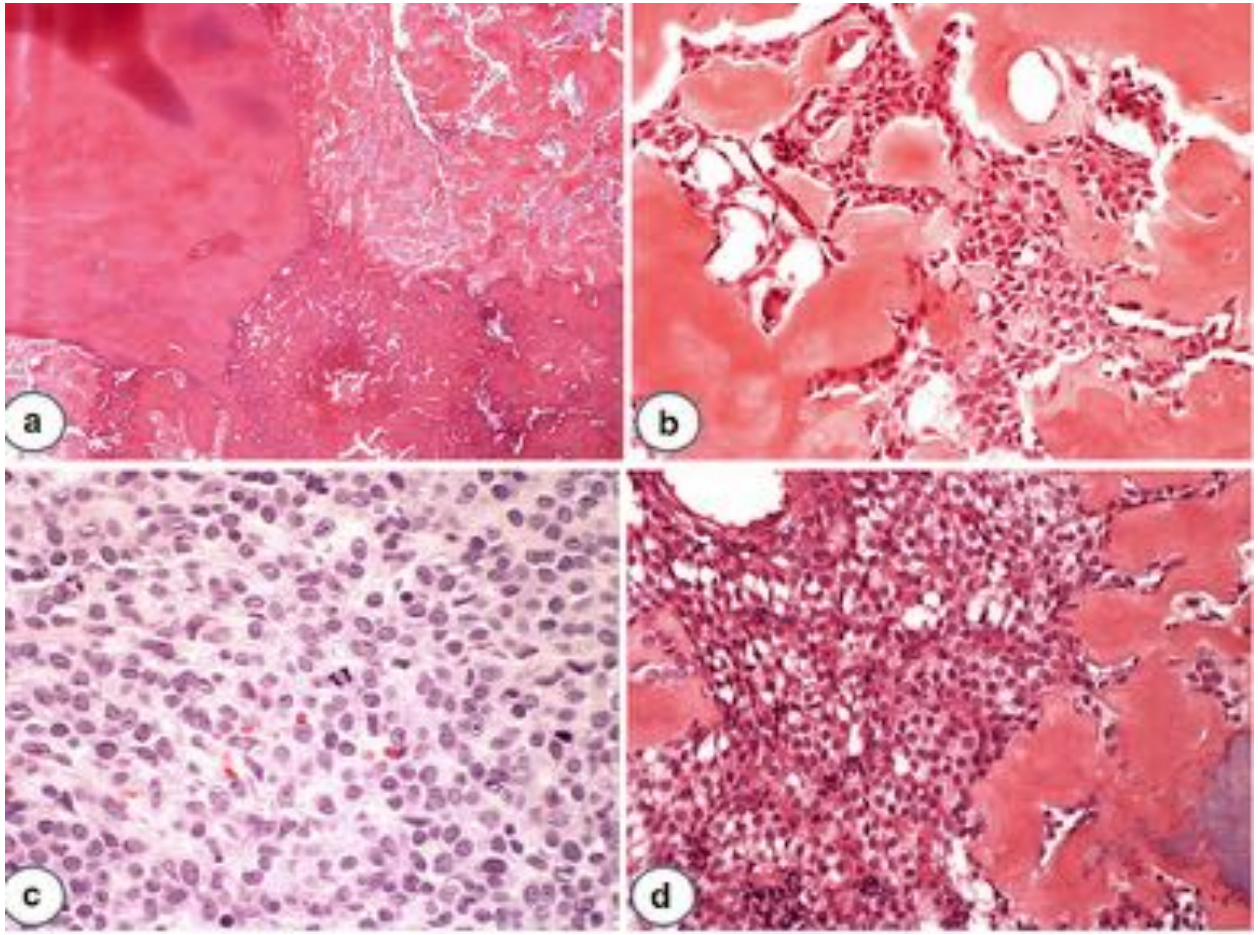

Head and Neck Pathol 2014; 8: 421-31

46-year-old female with root resorption of #18. Clinical diagnosis: periapical cyst

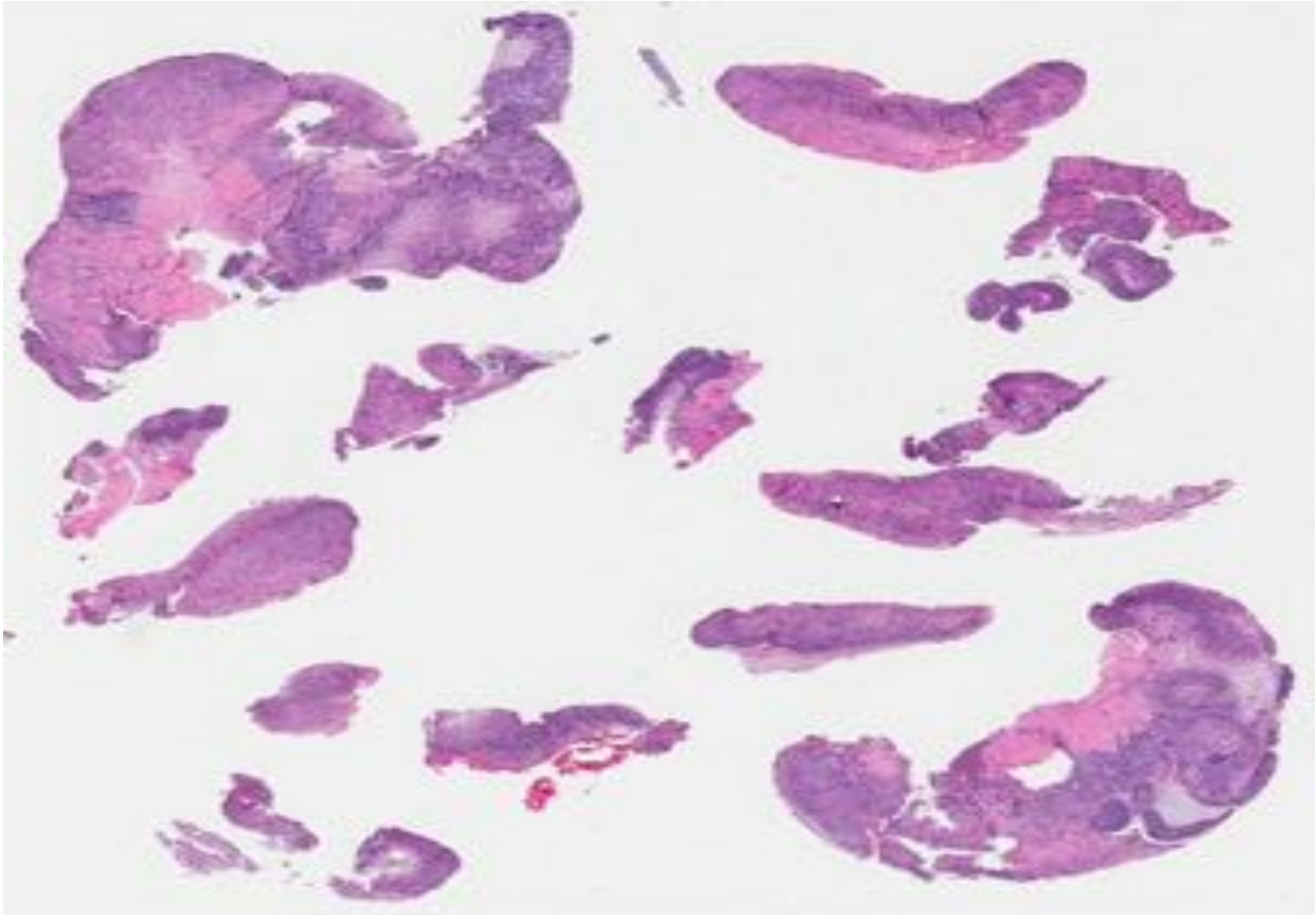

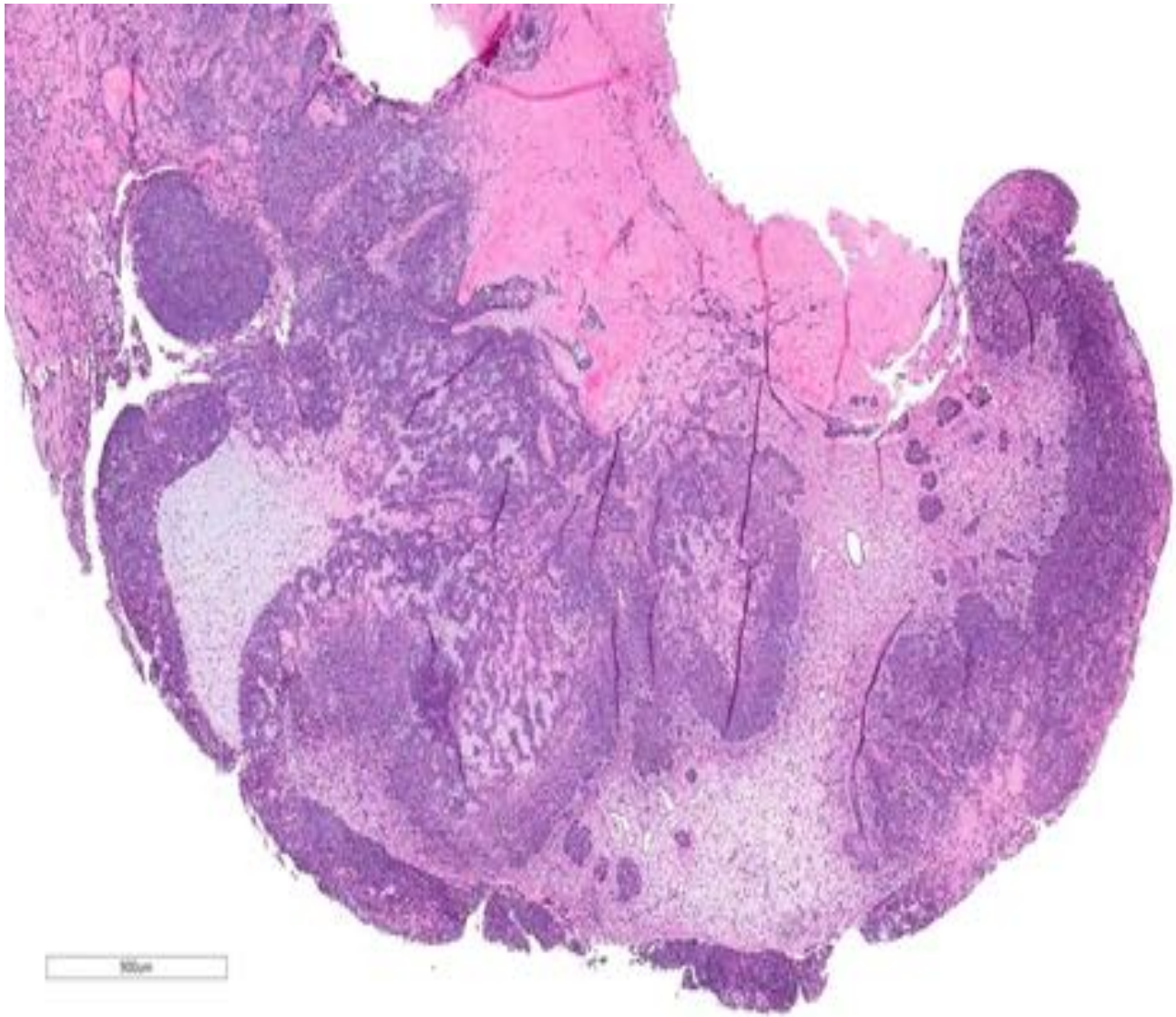
500µm

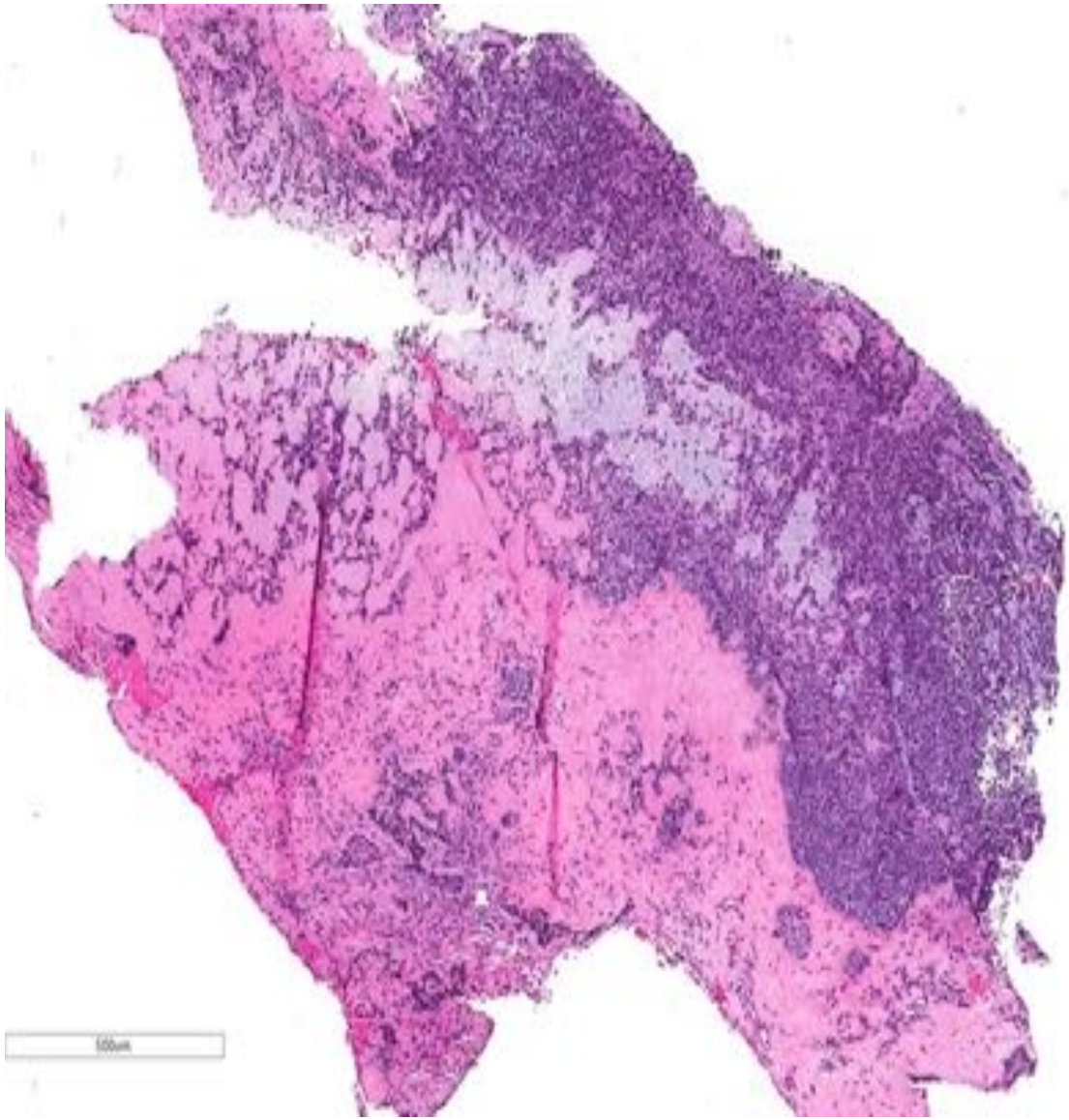
100um

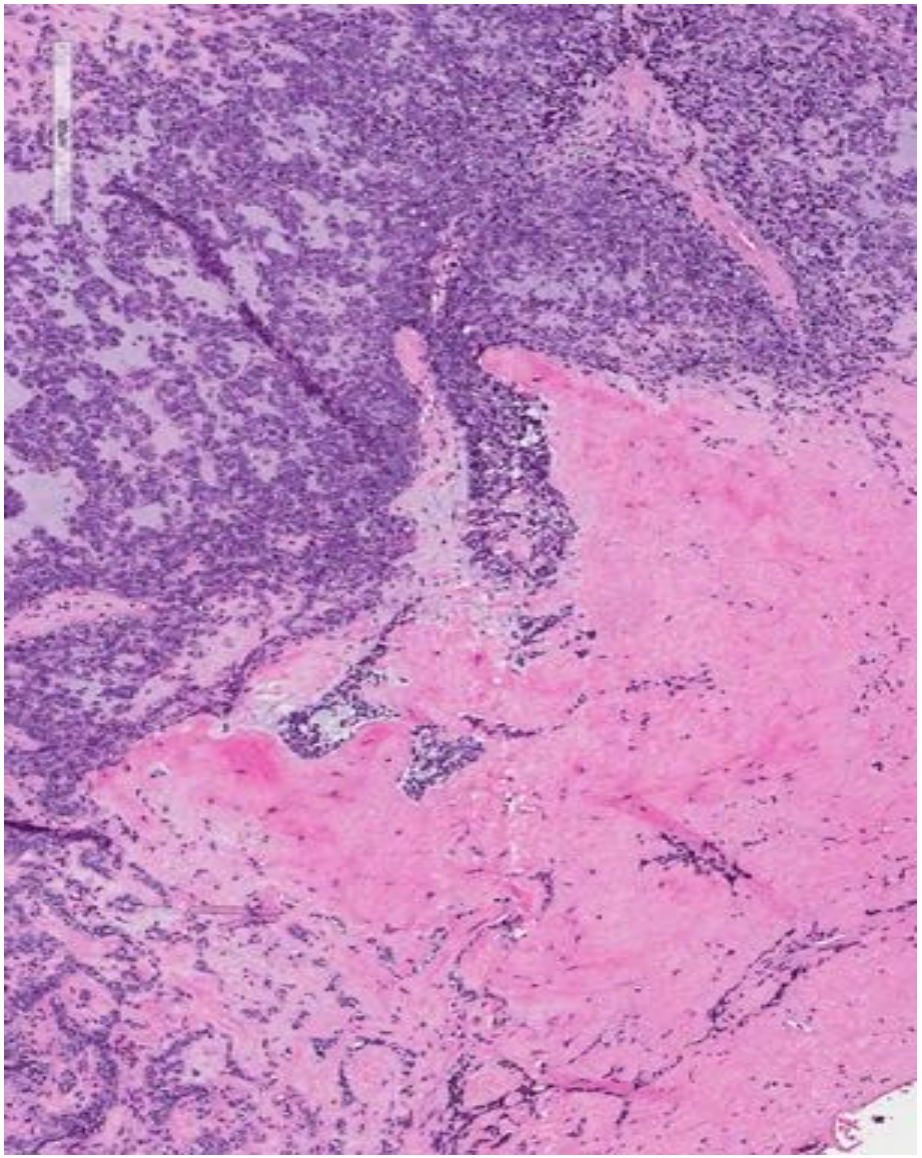

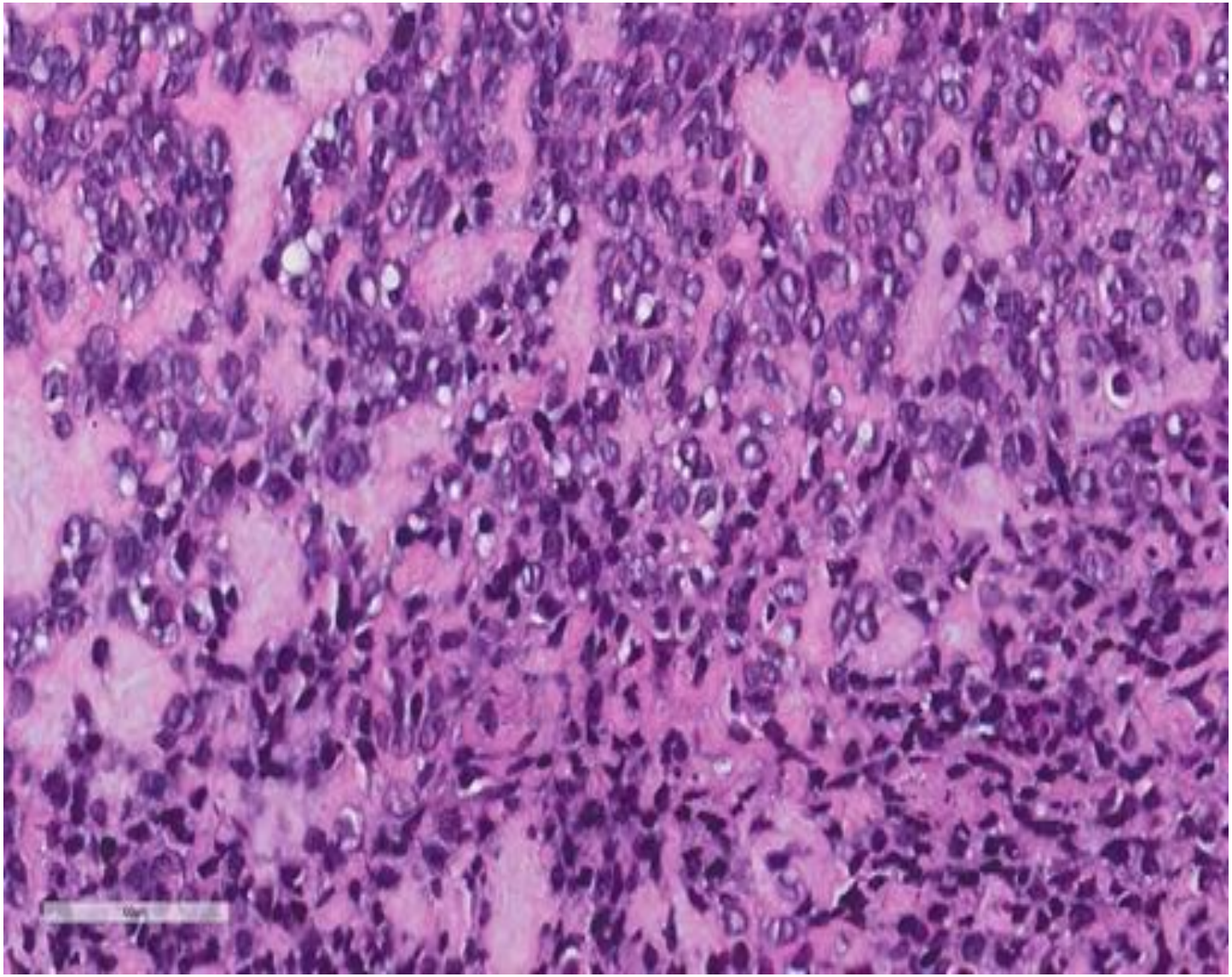

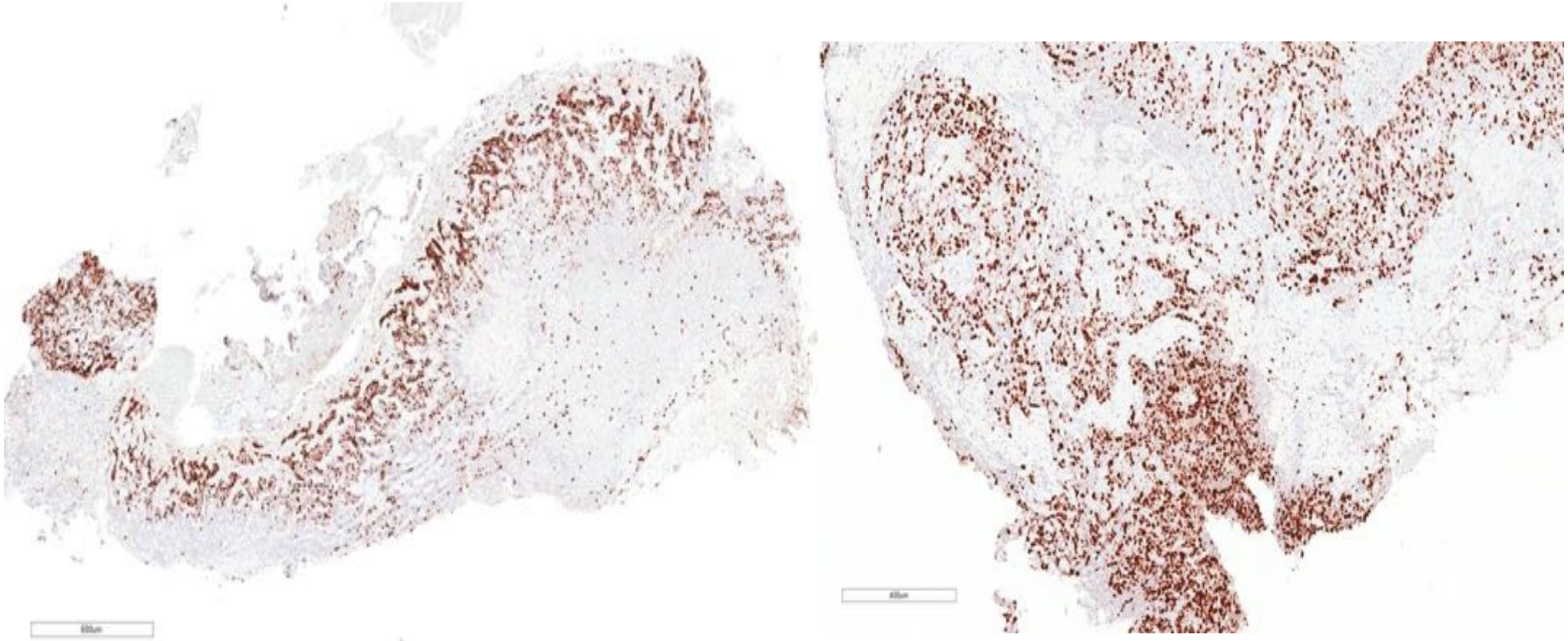

Ki67

Odontogenic Carcinoma with Dentinoid

Clear cell odontogenic carcinoma

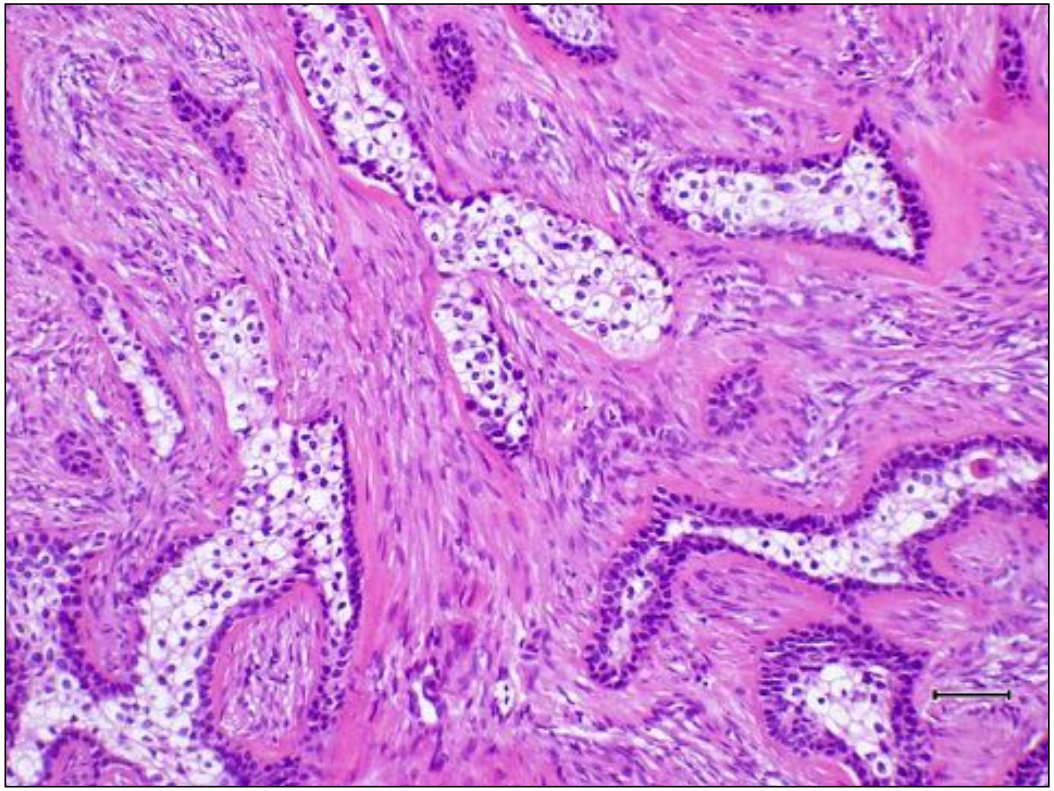

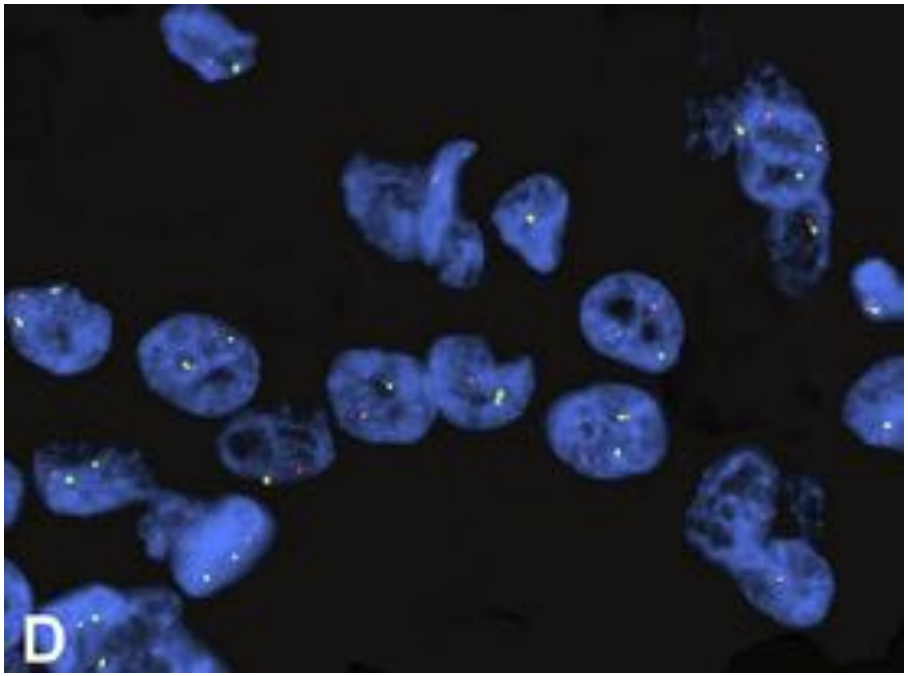

EWSR1 and *ATF1* rearrangements

Head Neck Pathol 2014; 8:400–410

Ghost cell odontogenic carcinoma

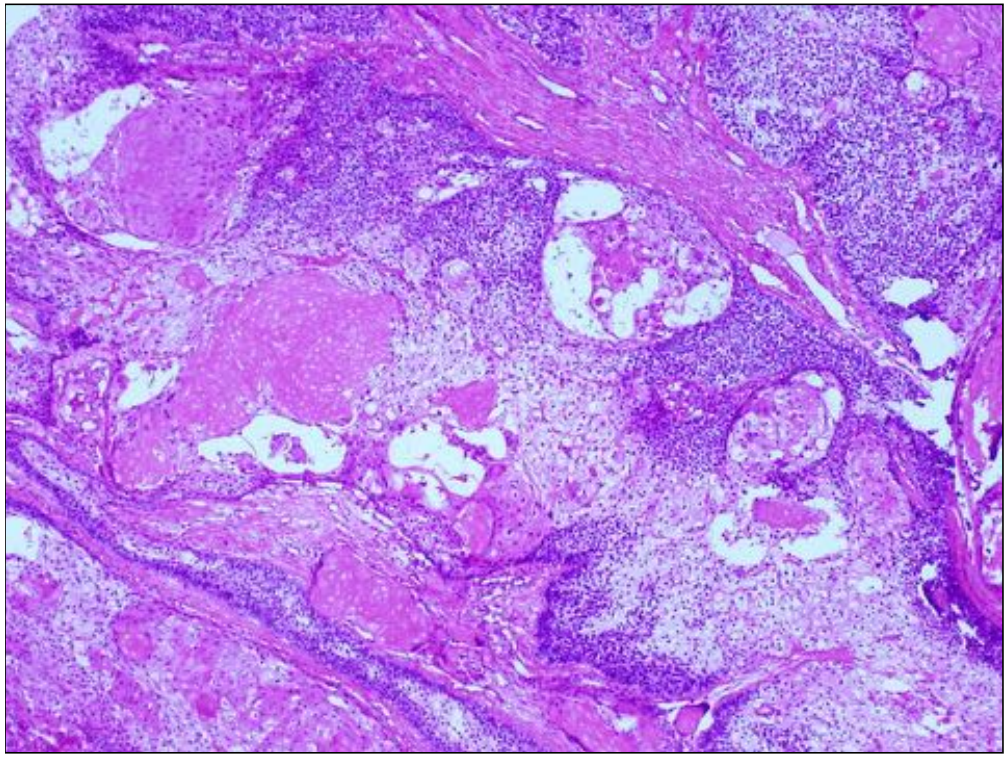

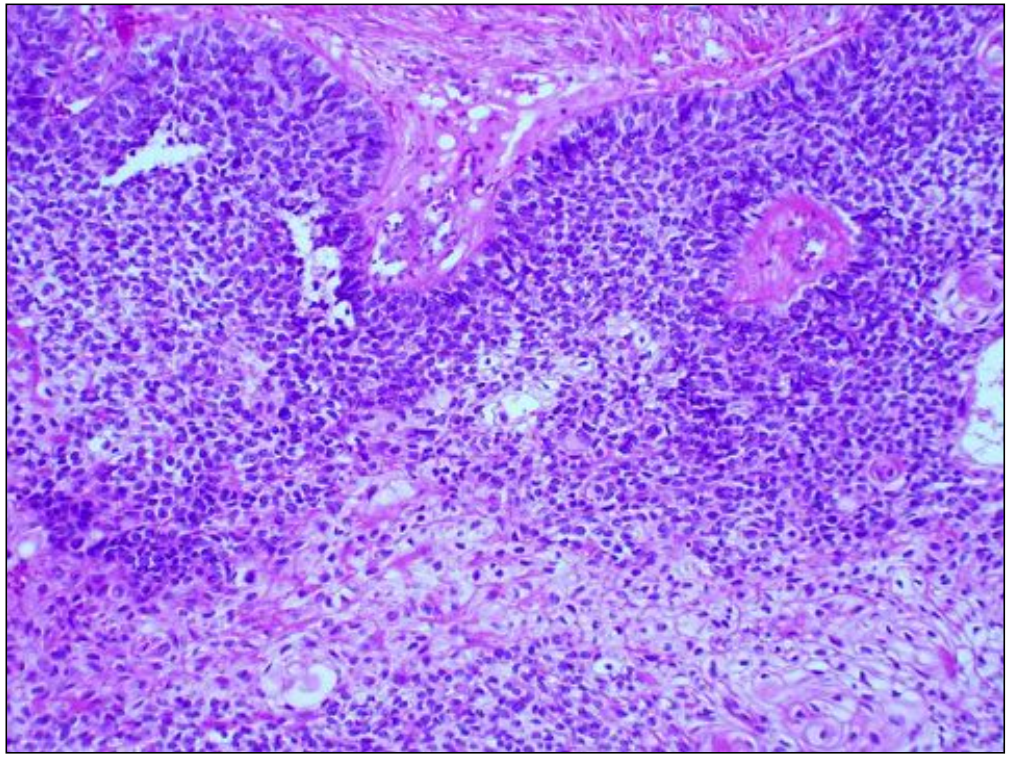

Thank you